

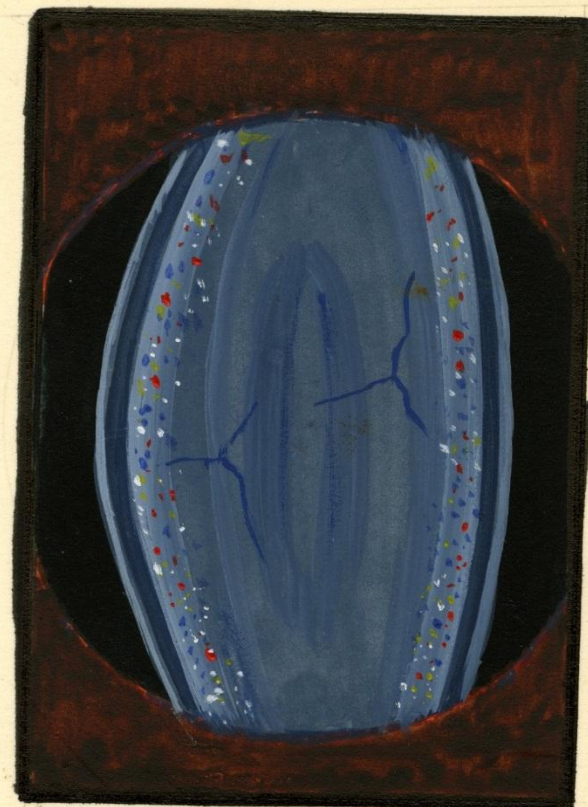
# Anterior Segment Paintings

by Ileen Hill



I. G. HILL

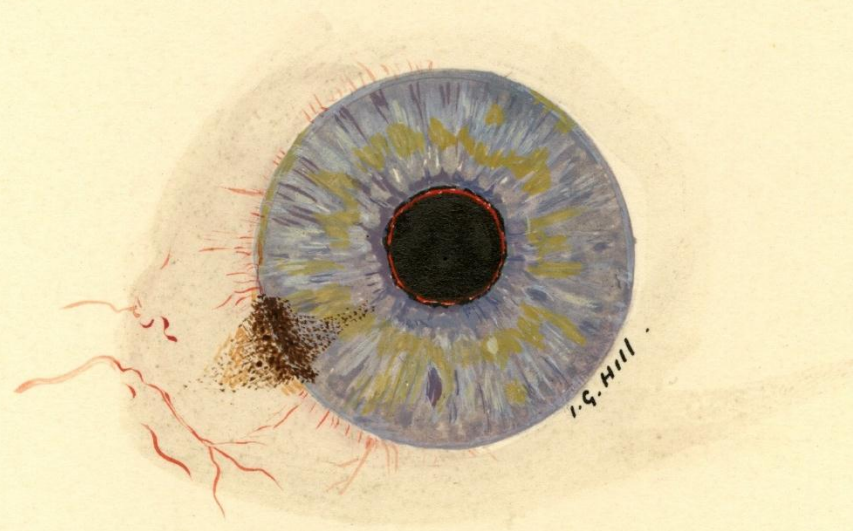
R



I. G. HILL



L



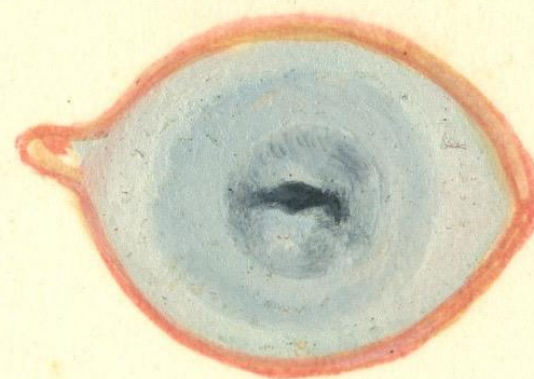
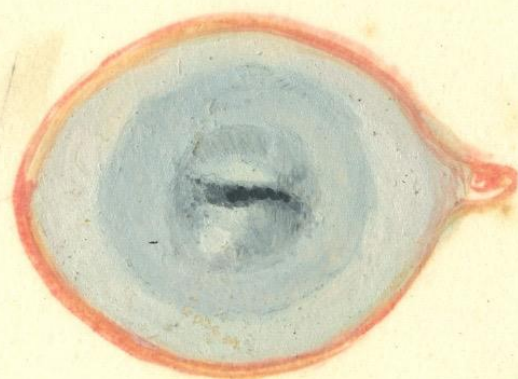


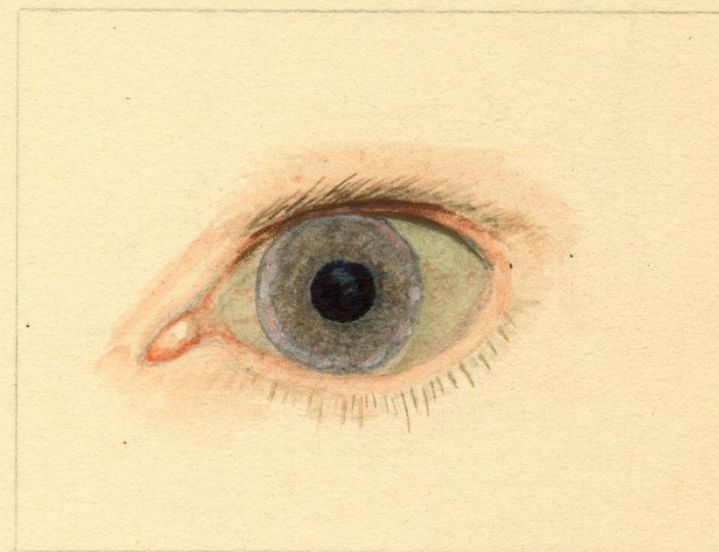
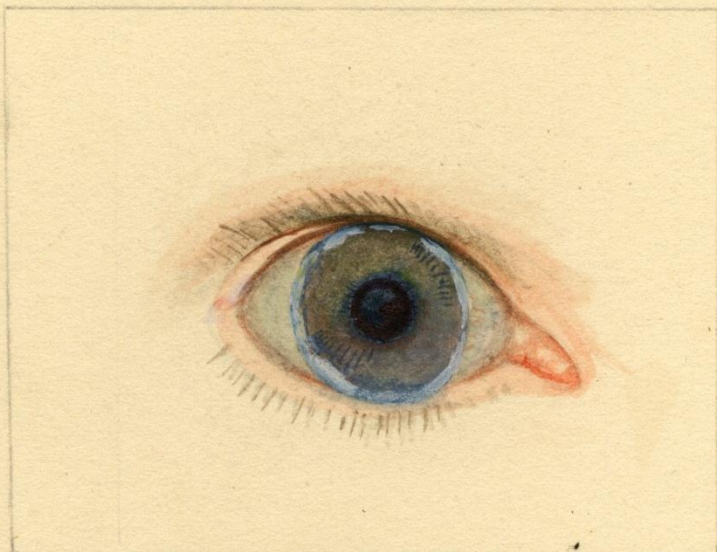Dr. A. Anderson.

1895









Chas. H. H. H.














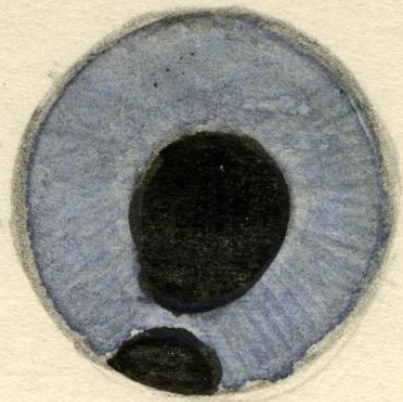
R.E.



L.E.



6 months old boy



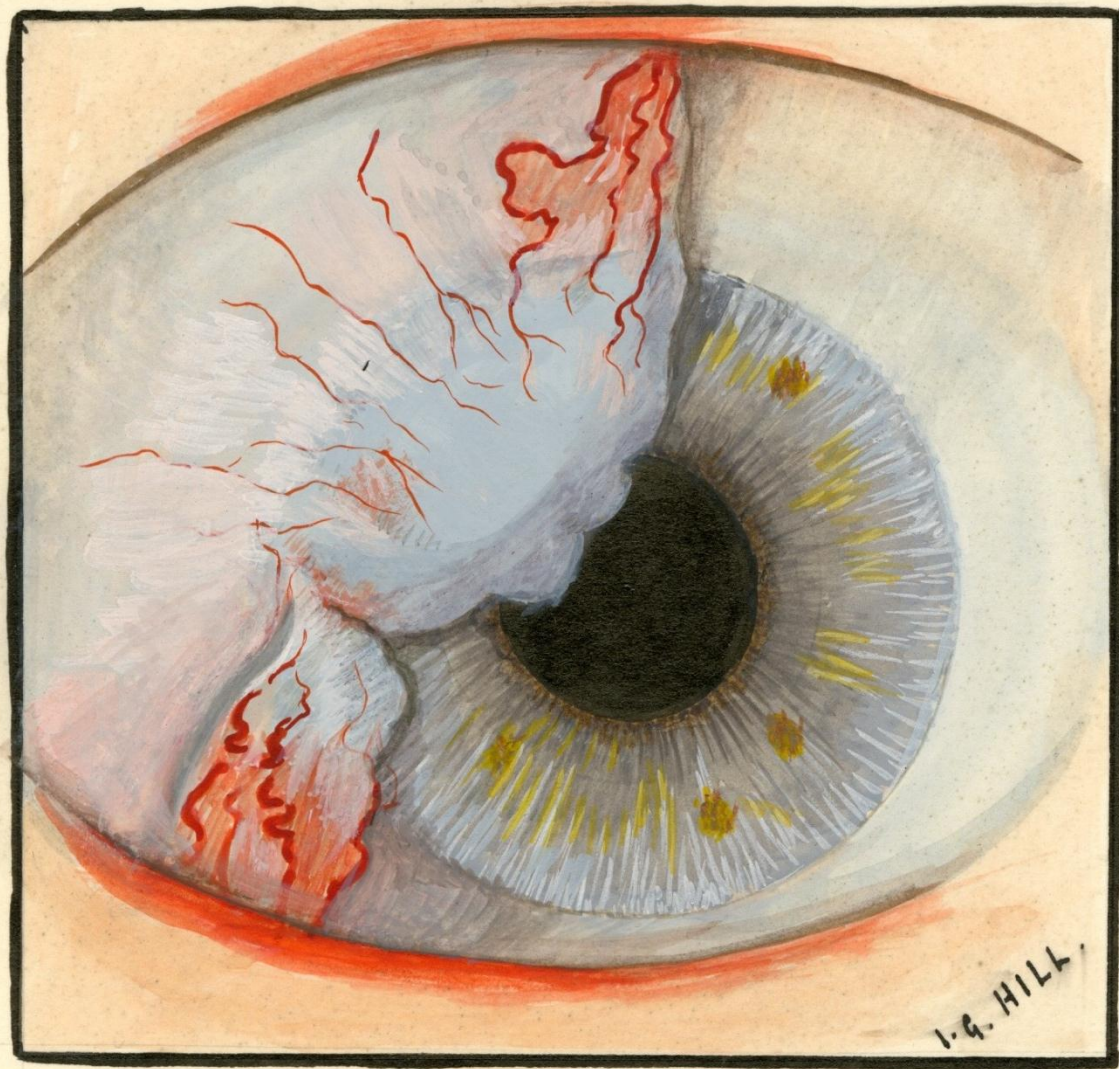
R.E.



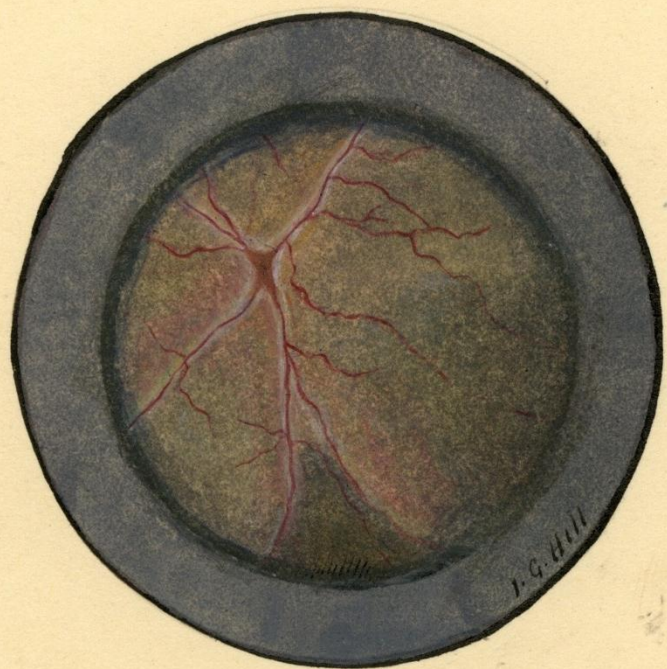
L.E.

*Colobus boma*









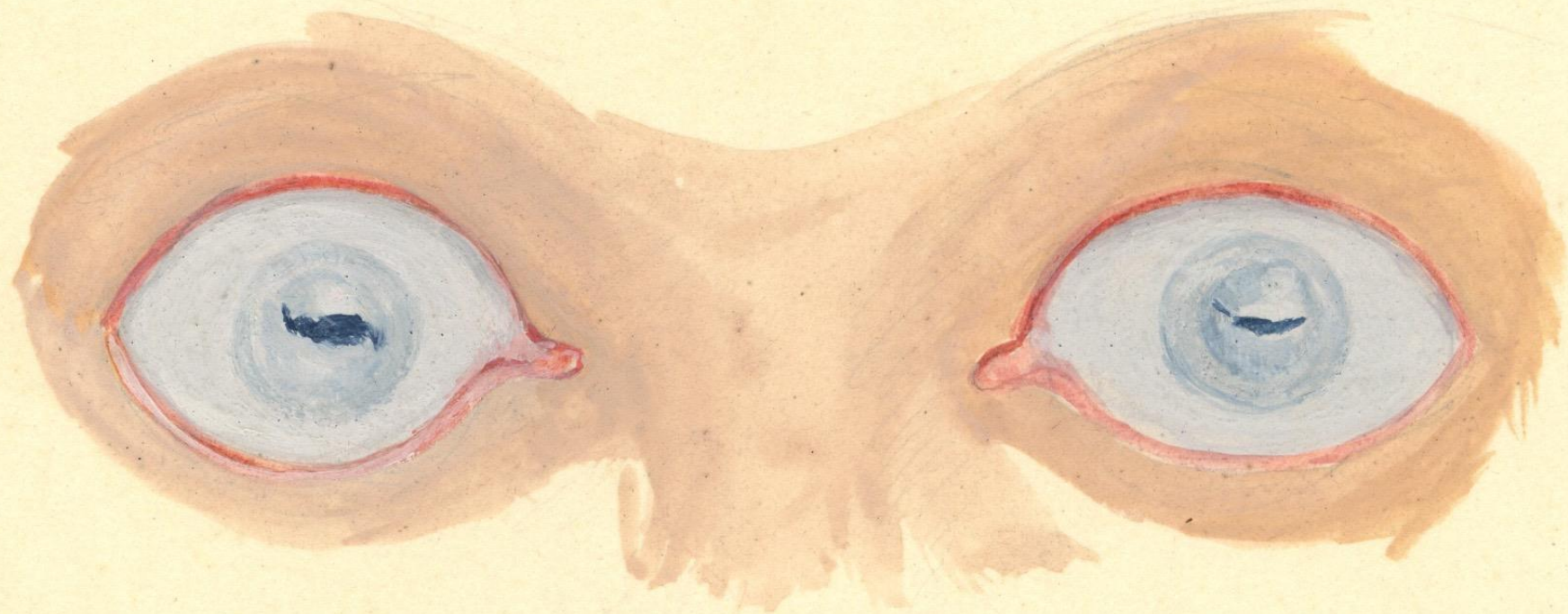




Dr. N. Lewis.










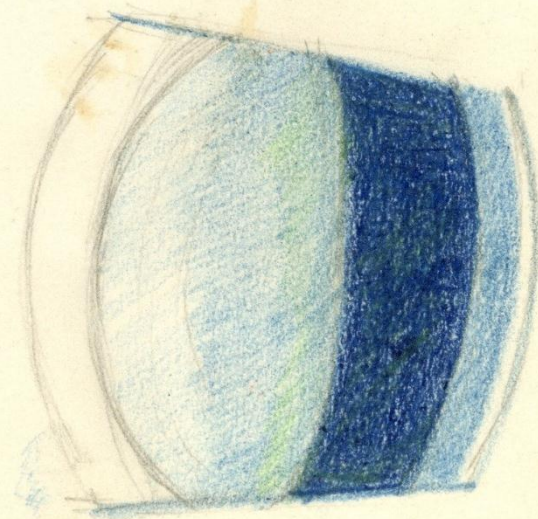





I. G. HILL

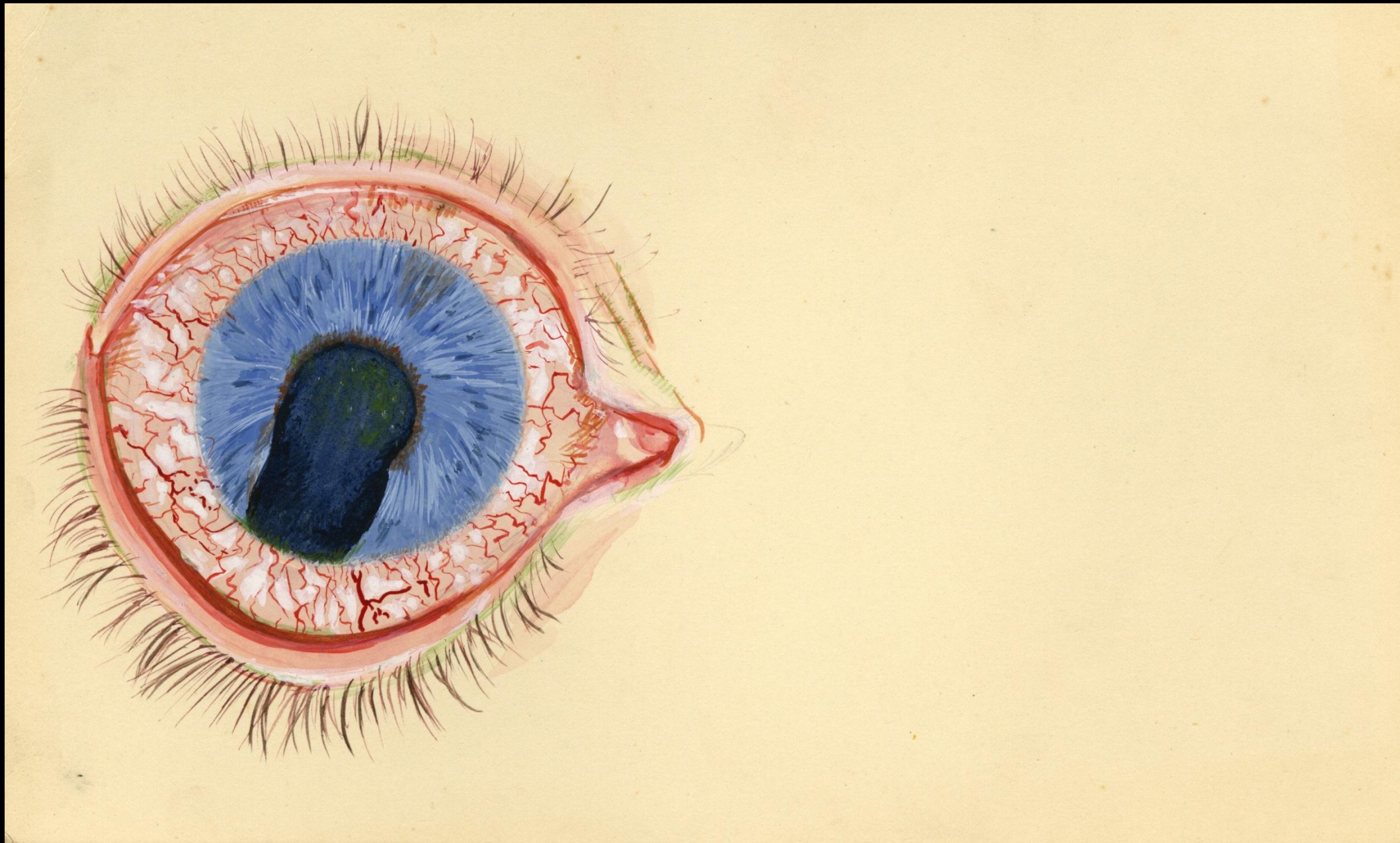


I. F. B



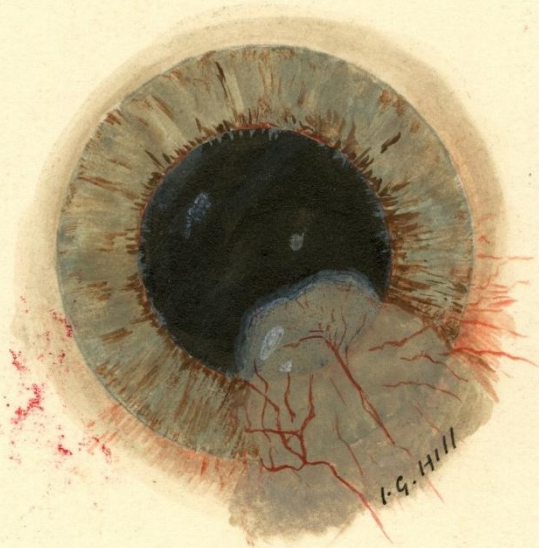






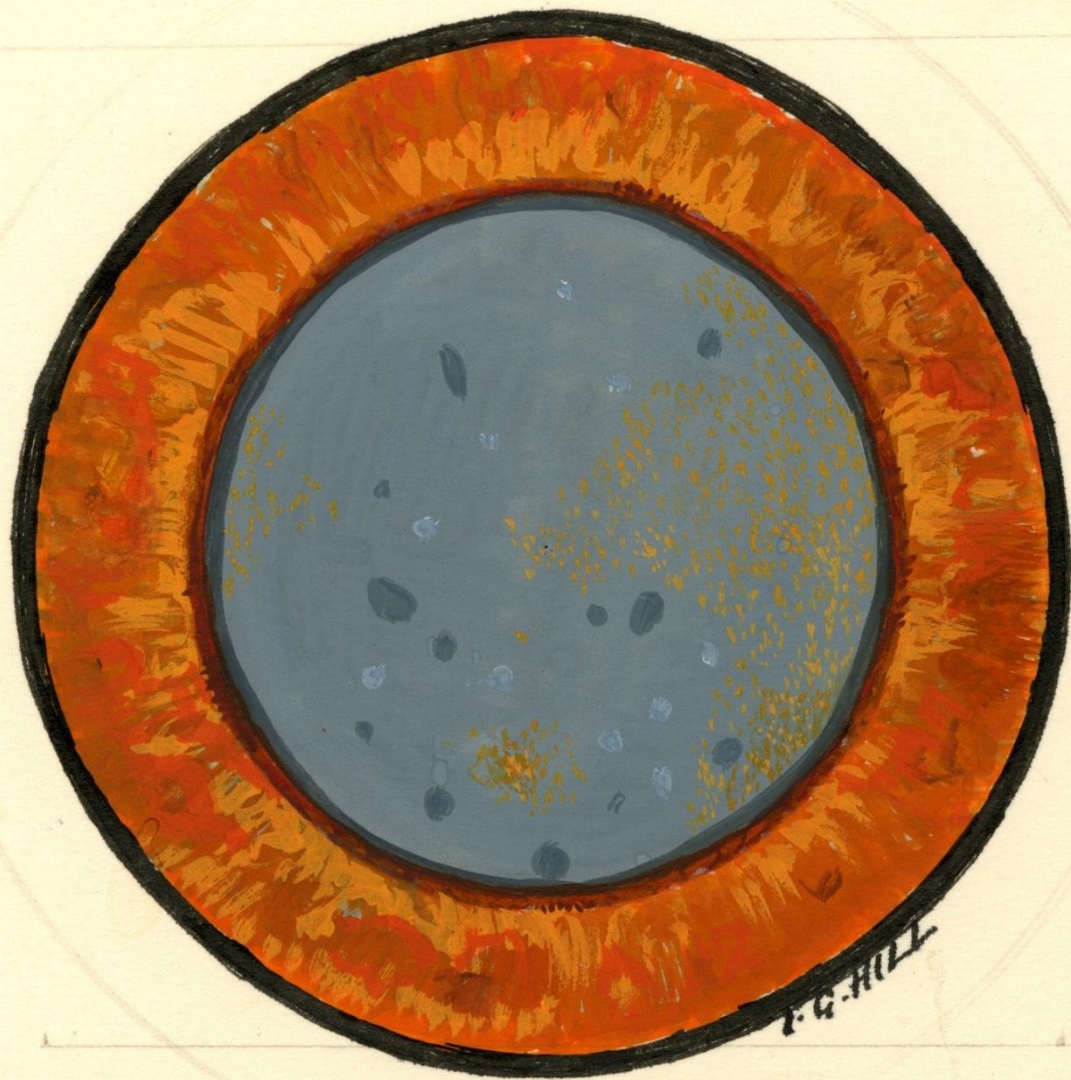


L/E.  
Possible sarcoidosis.  
Xray of chest  
W.R. negative. Mantoux negative.



Eye and Ear Hospital



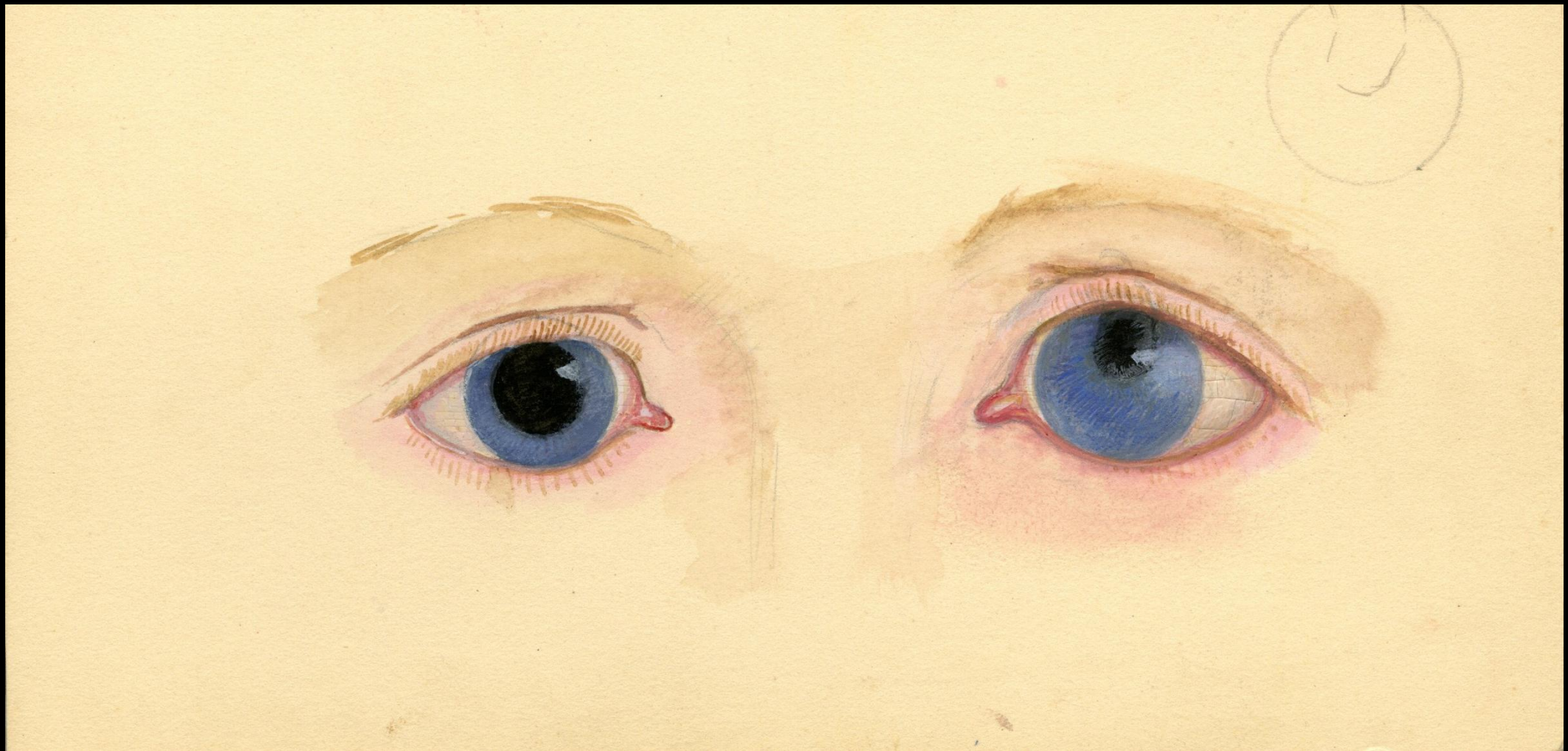

F.G. HILL

MED EYE  
SERVICE

DR. TROTSKI, R1

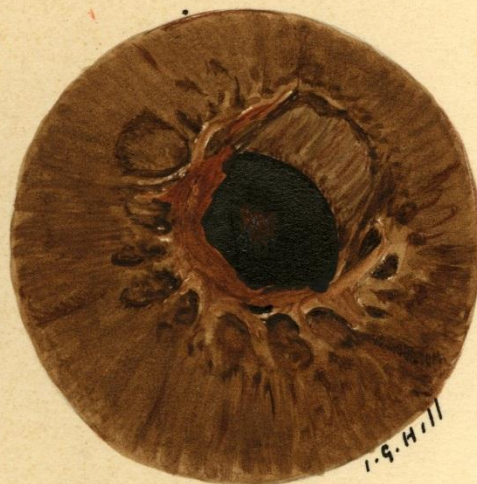



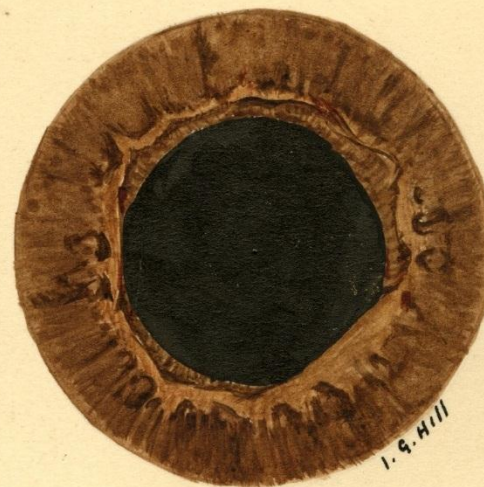




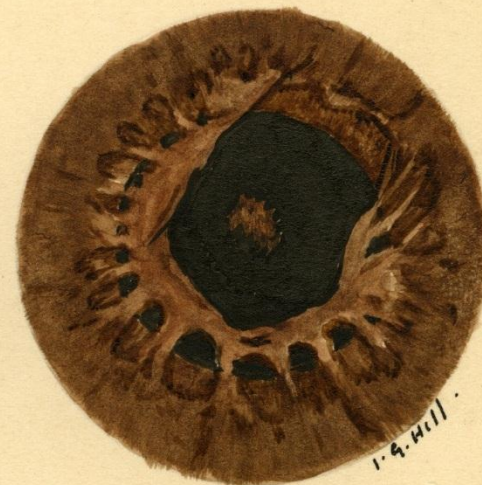
L.E.



R.E.



L.E.



R.E.

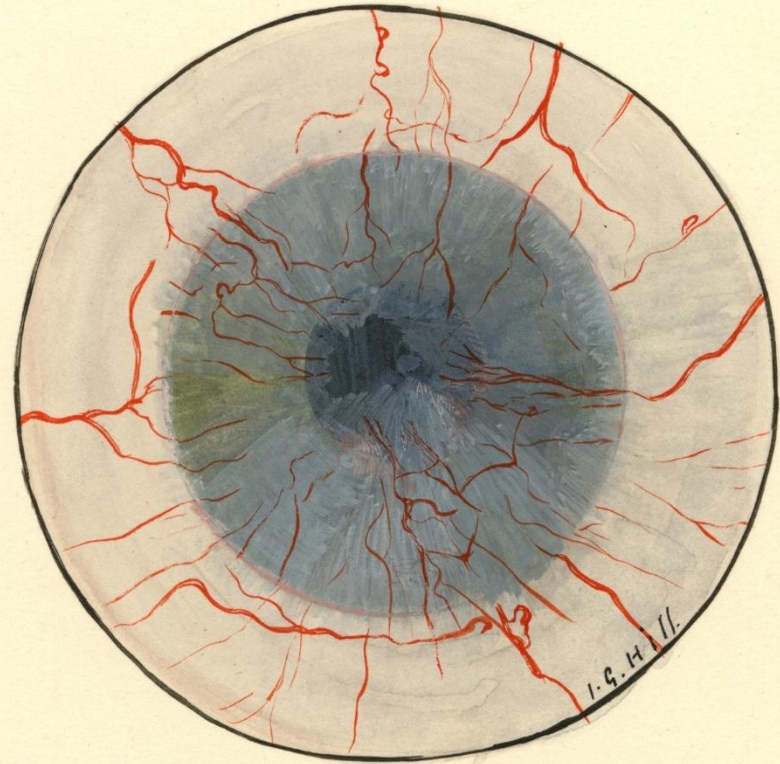

Undilated

Dilated

Dr. R. L. Naylor.


49



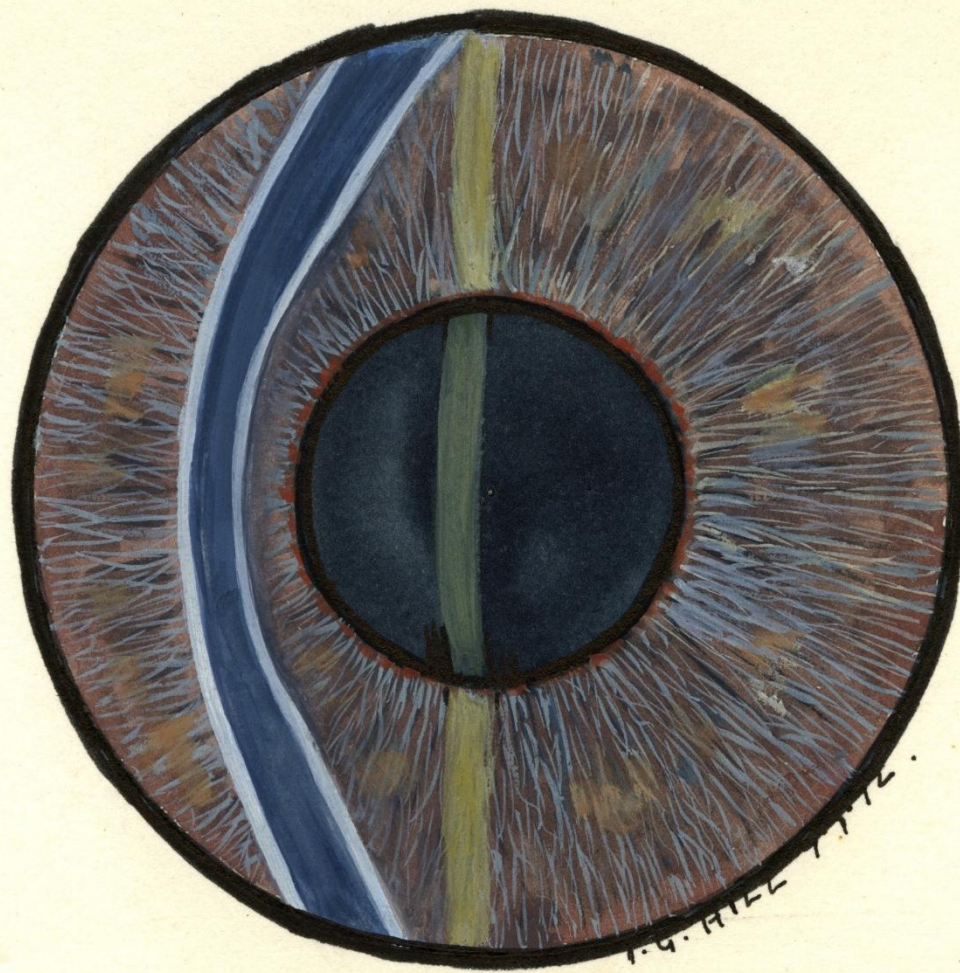


Dr. R.L. Naylor.









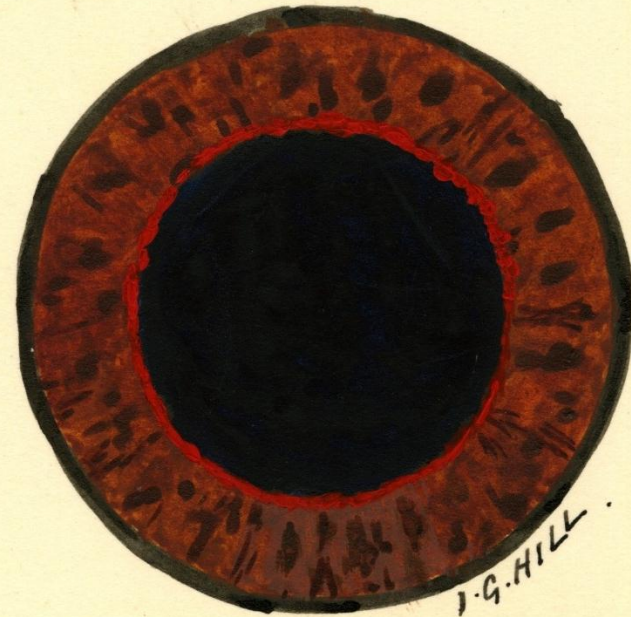
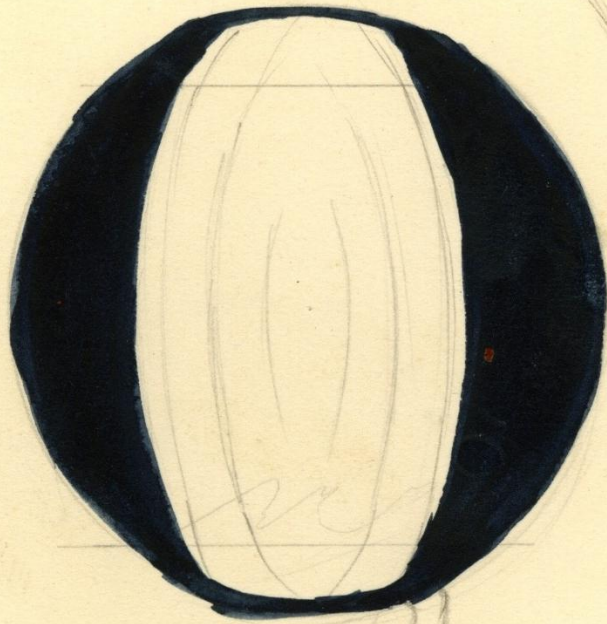
I.G. RILEY 1972.



30-6-88 '30/6/88

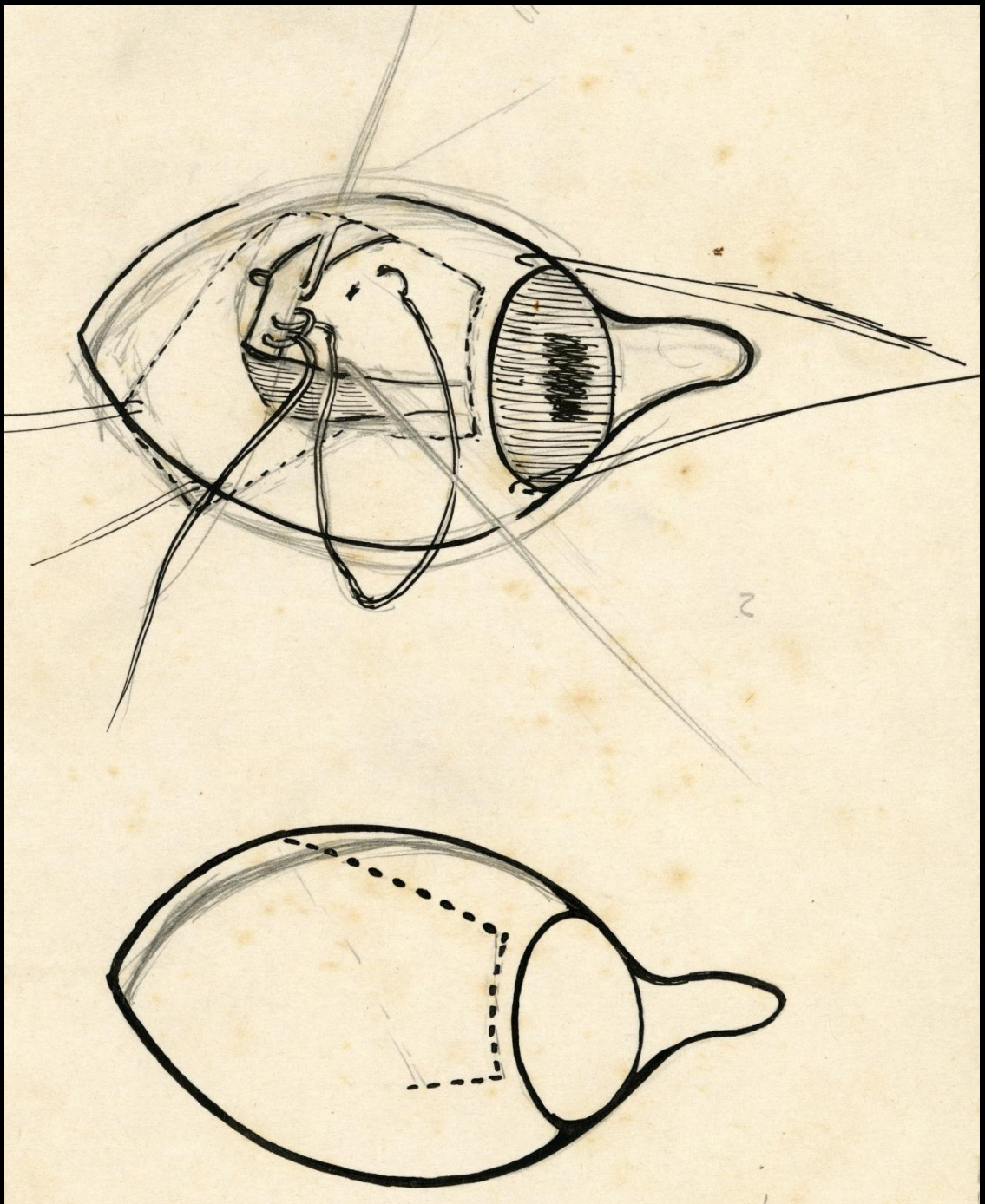




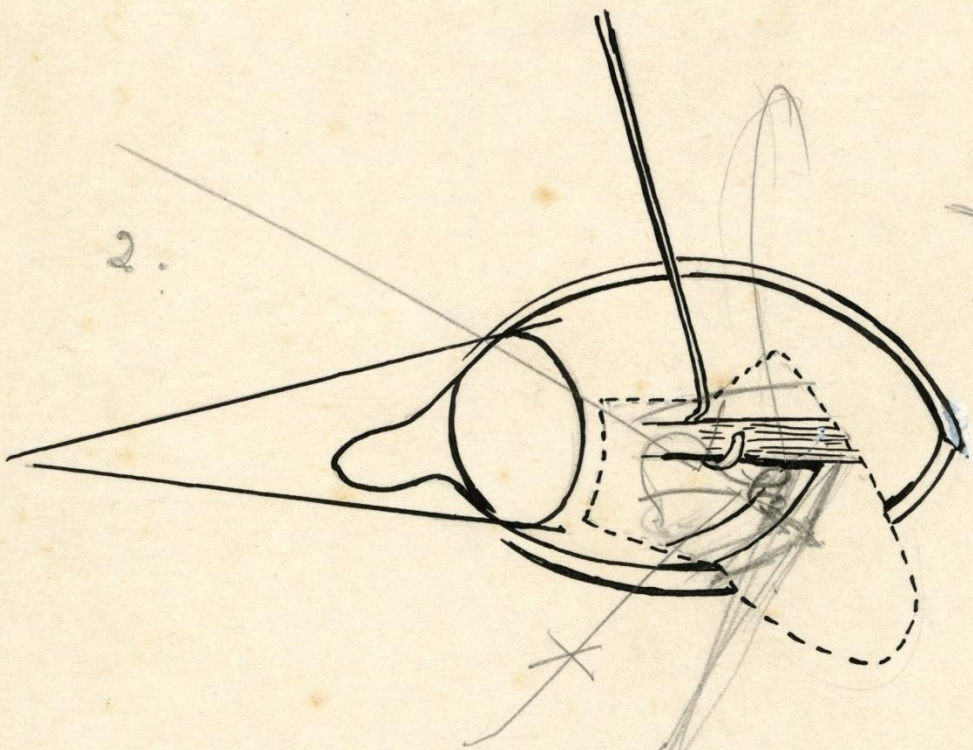
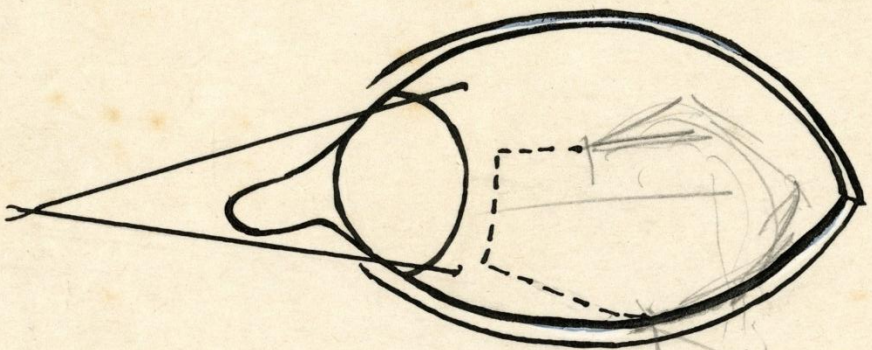


I.G.HILL





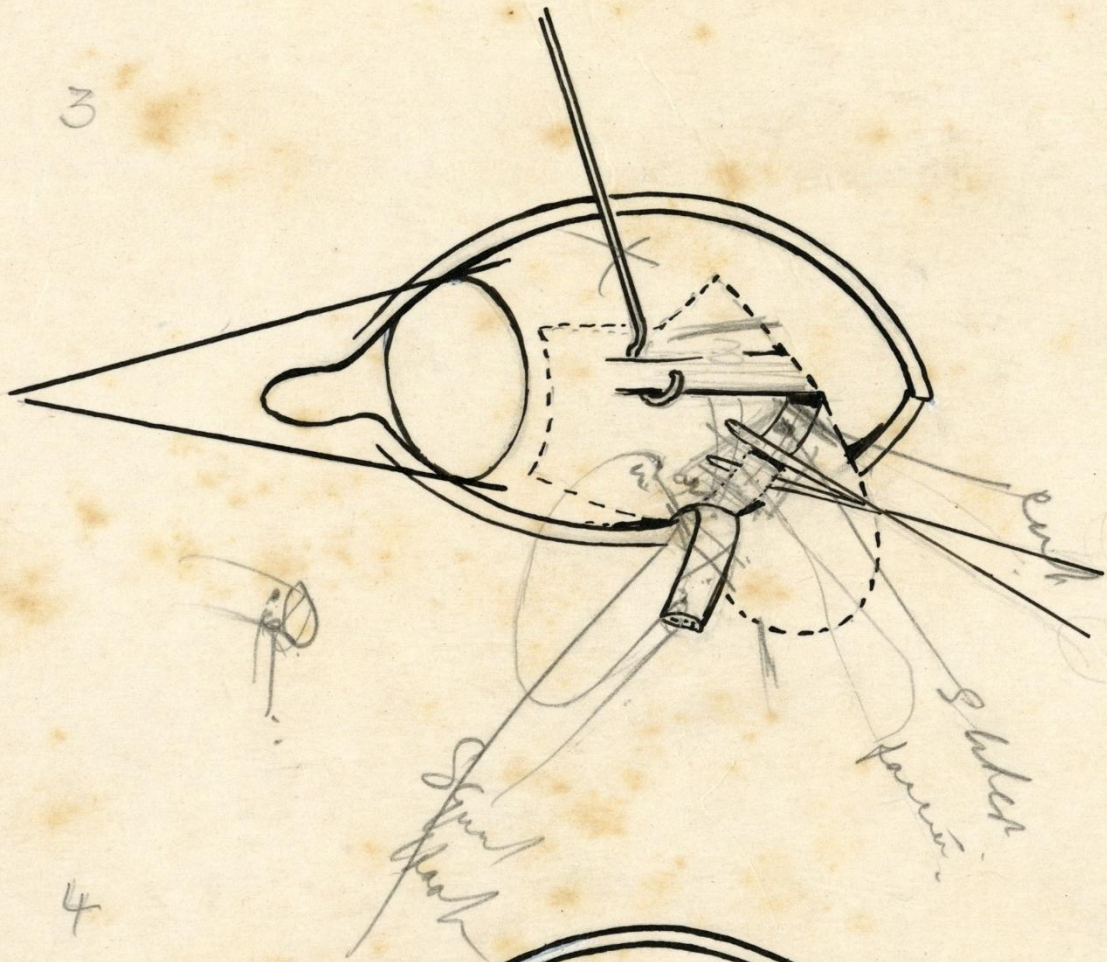




2.



3



4

