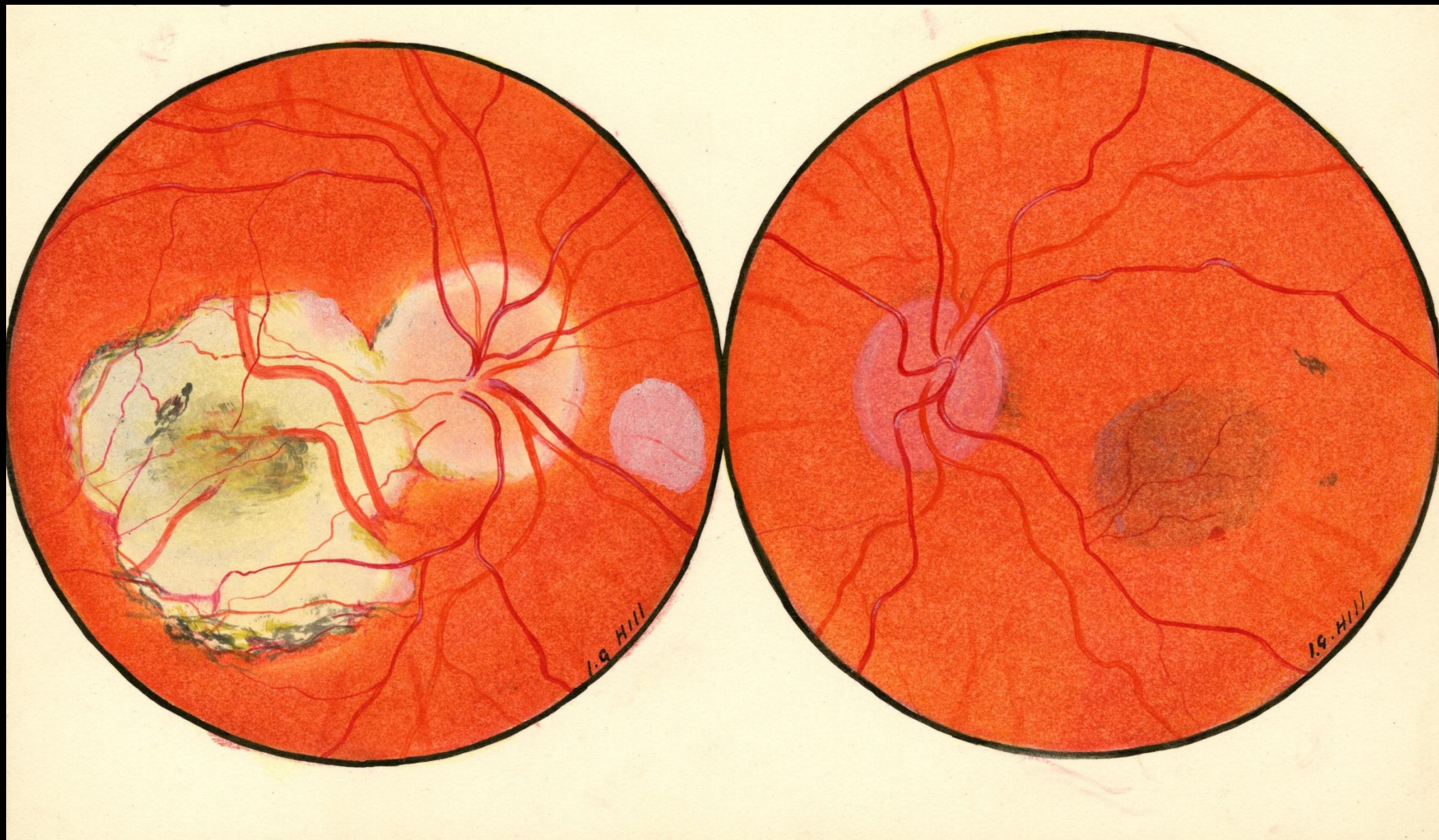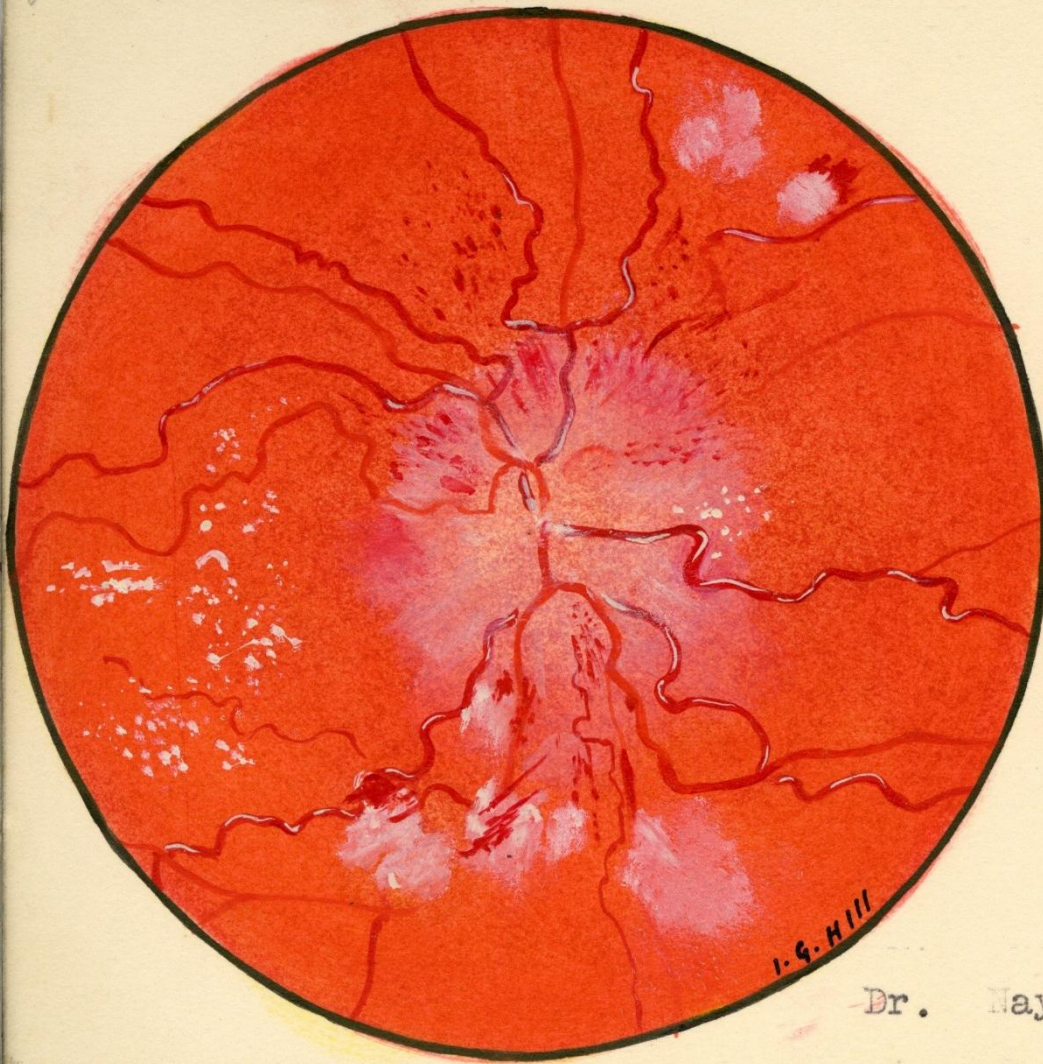
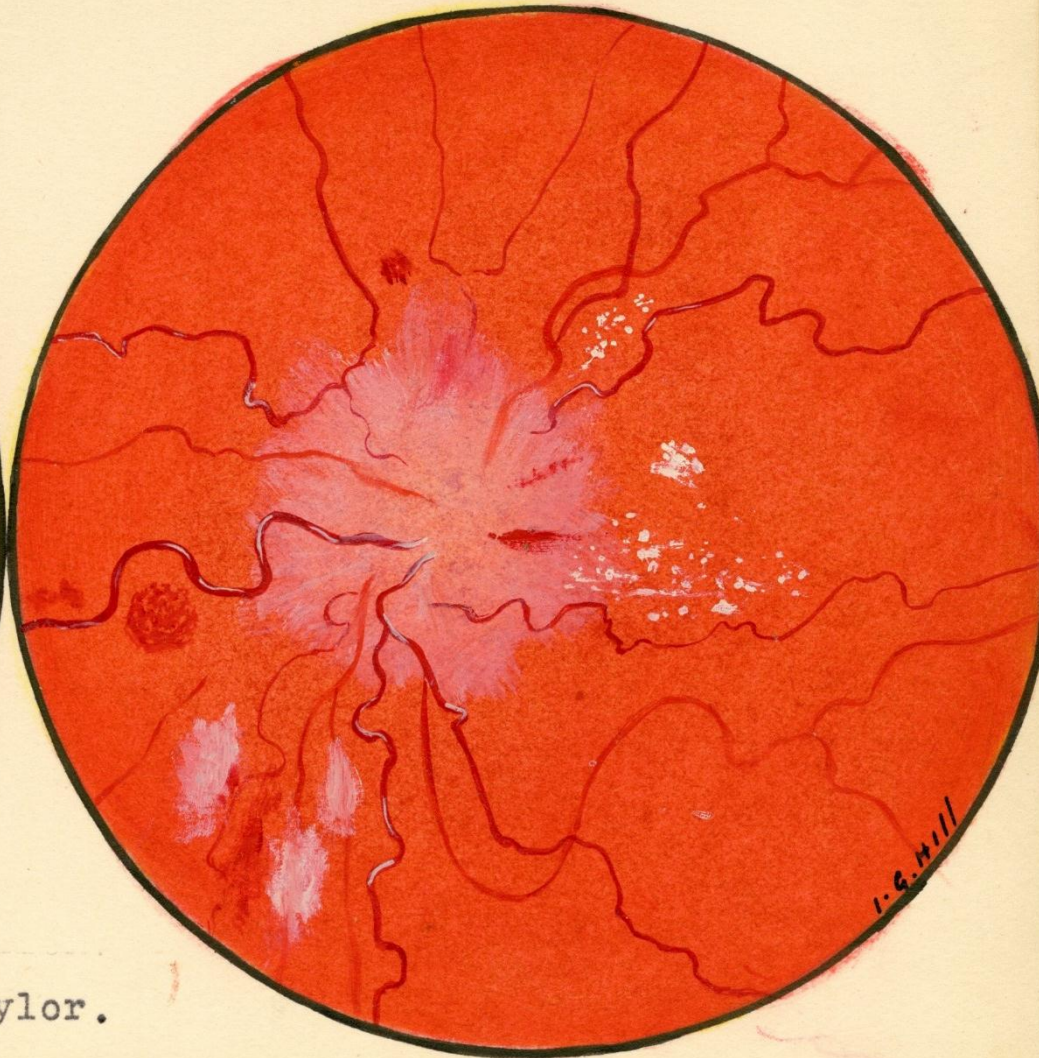


Posterior Segment Paintings by Ileen Hill





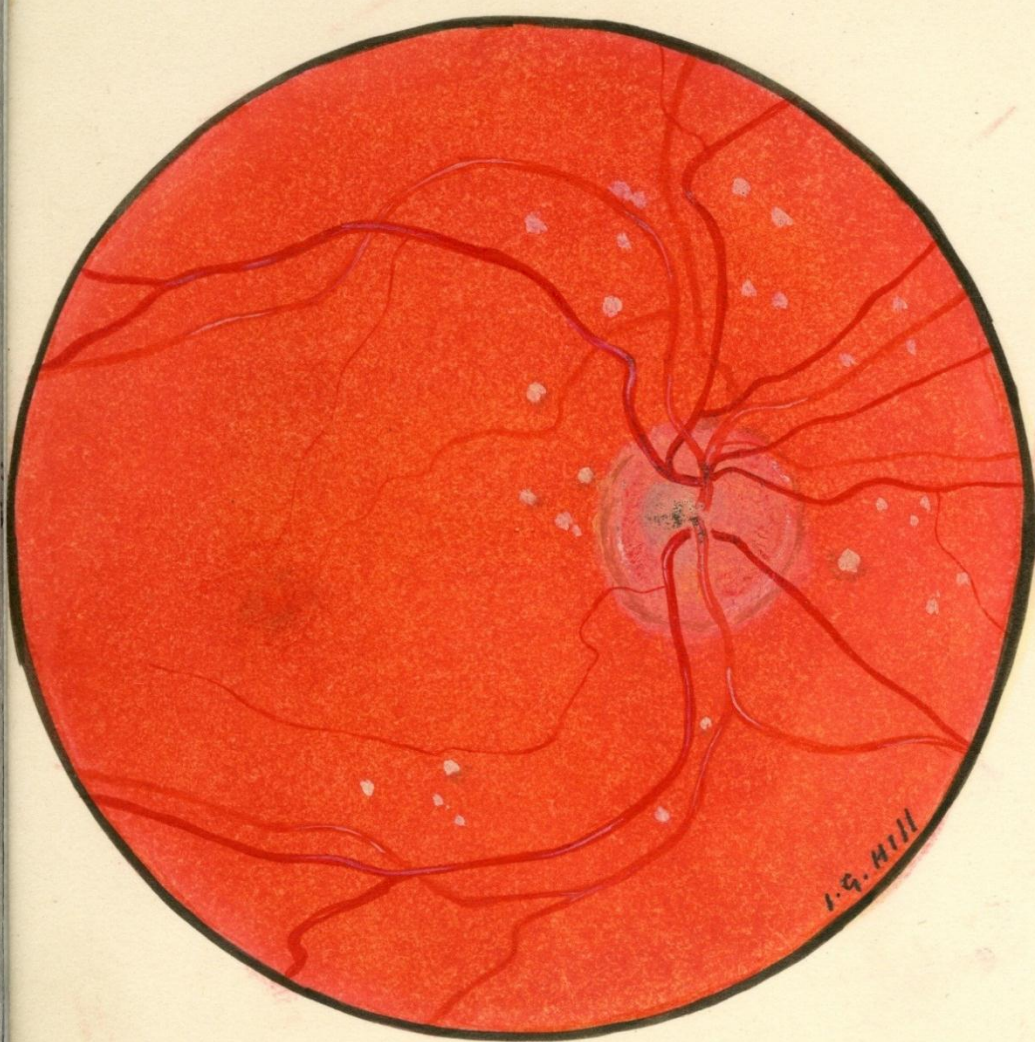I. G. Hill



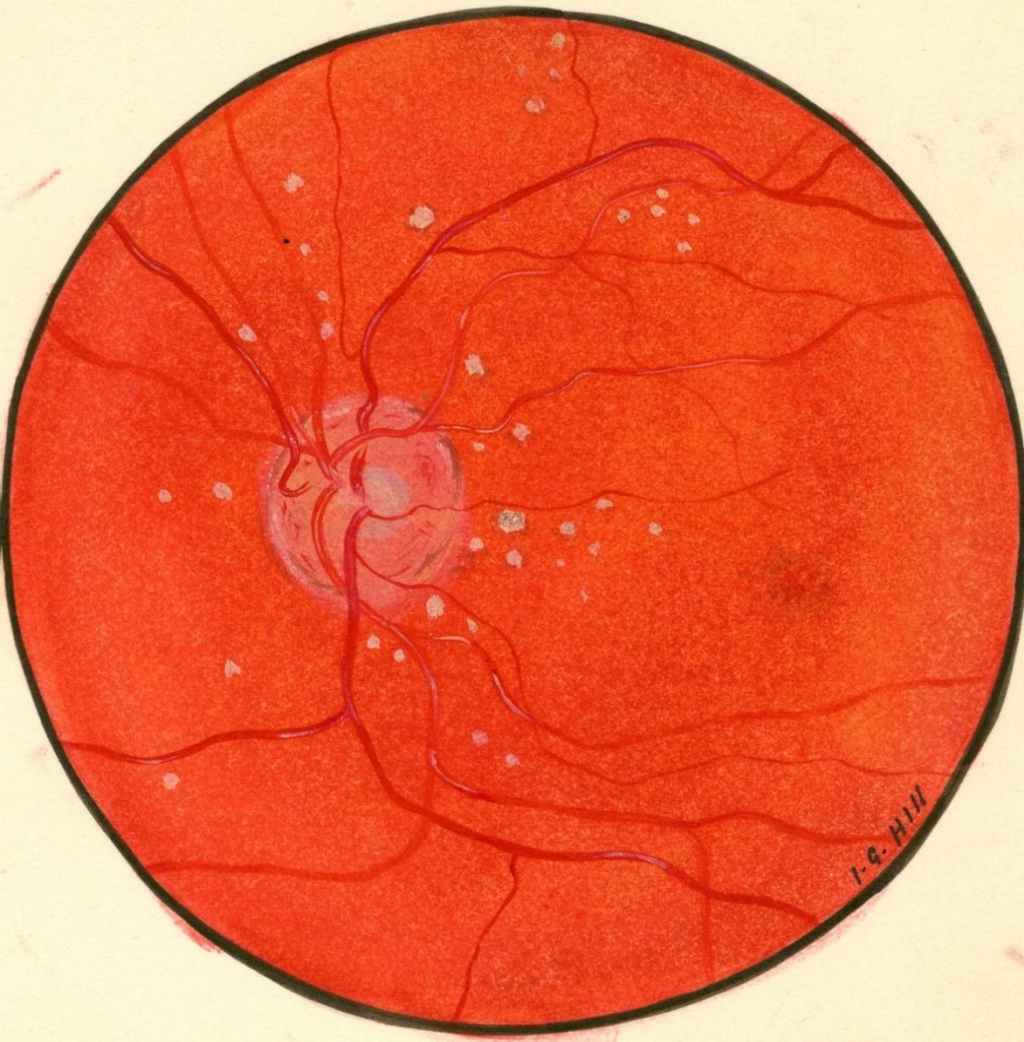I. G. Hill

Dr. Naylor.

34



I. G. Hill



I. G. Hill

23 yrs. Embolism of L.C.R. Artery (7.6.51)

21/6/51.

23 yrs.

CONFINEMENT 7.6.51

P.P.H.

PLACENTA EXPRESSED

NO BLOOD TESTS B_4 CONFINEMENT.
BLOOD TRANSFUSION. IN LEFT ARM
 $1\frac{1}{3}$ MG ^{THEN} FLOW STOPPED.

R.T.F. REPEATED IN RIGHT ARM
3 HRS LATER. $\frac{1}{3}$ MG ^{4 HRS} STOPPED.

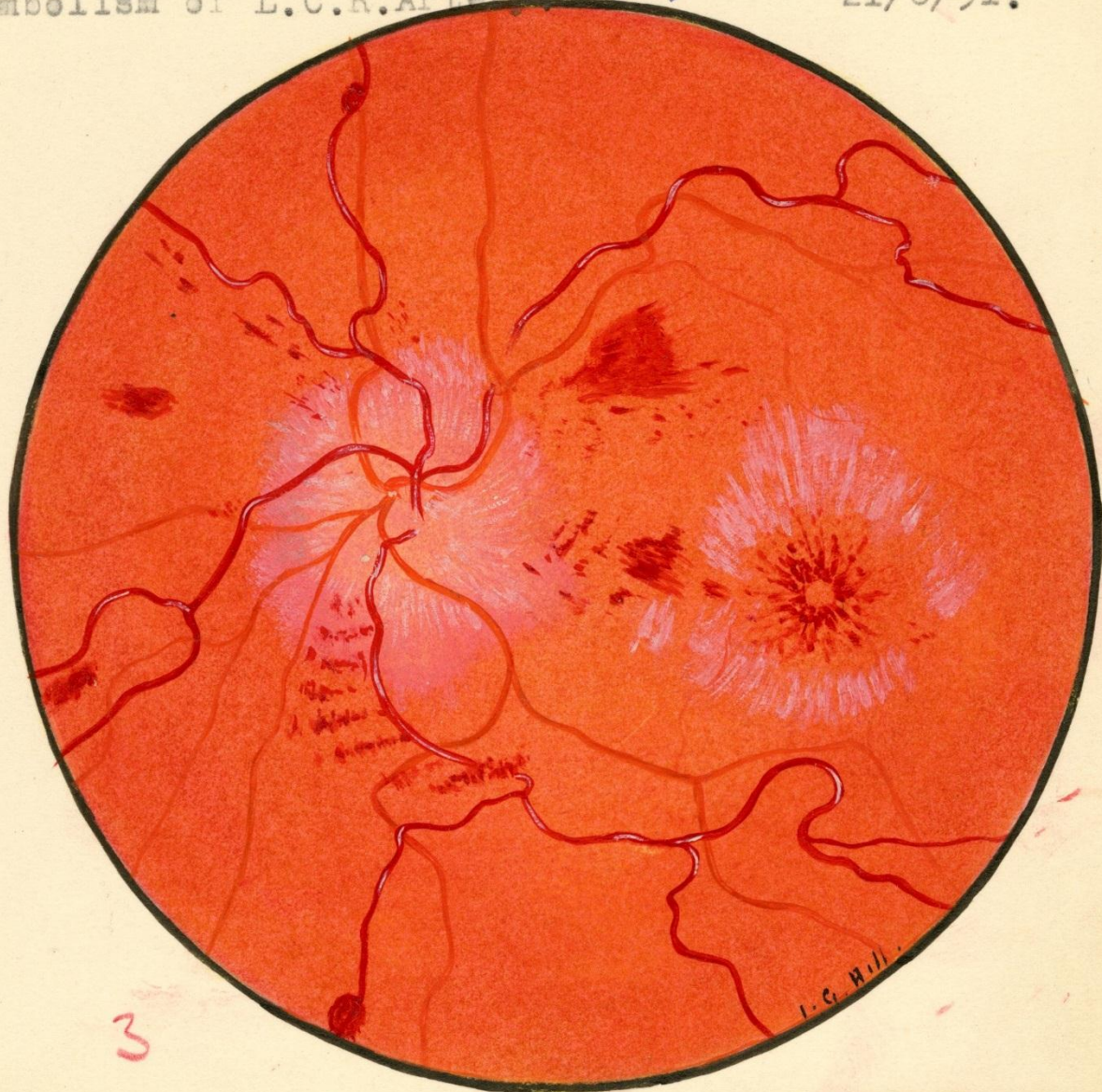
3rd BOTTLE GIVEN ^{4 HRS} LATER,
FOLLOWED BY REMAINS OF
2nd BOTTLE WHICH STOPPED
AGAIN AFTER $\frac{1}{8}$ MG HAD RUN IN.

NEXT DAY SIGHT of L. EYE.
WAS BLURRED.

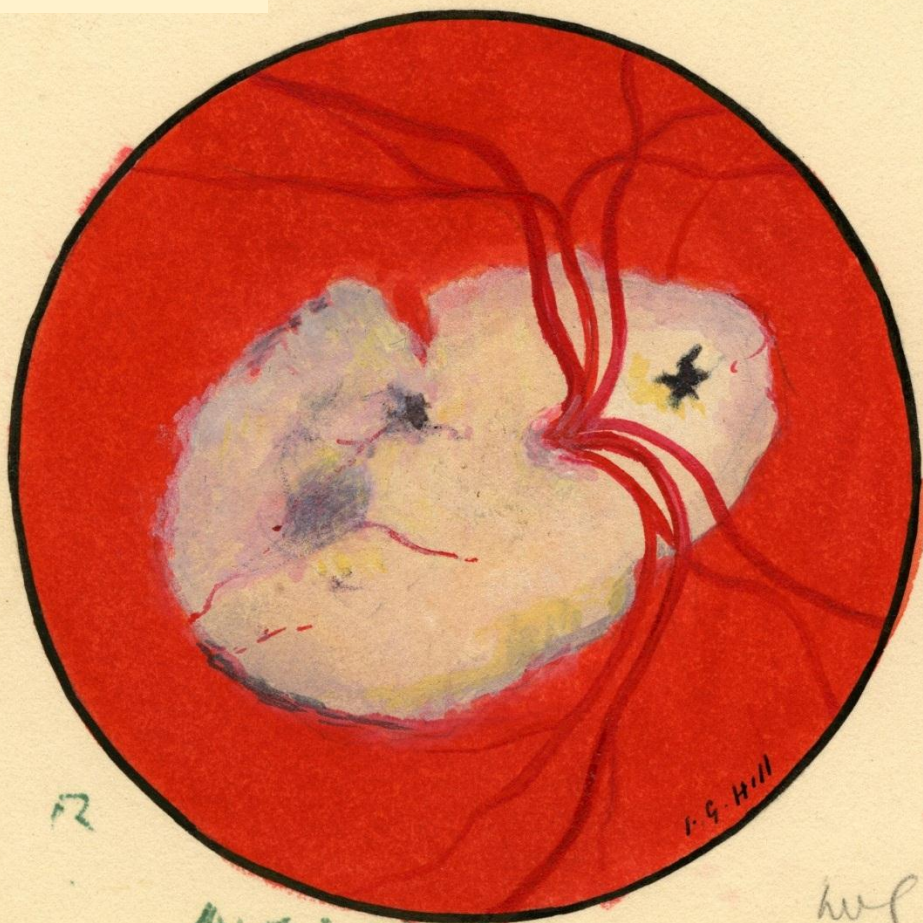
REFERRED BY OPTICIAN

Dr. R. L. Naylor.

C. I. A.



3

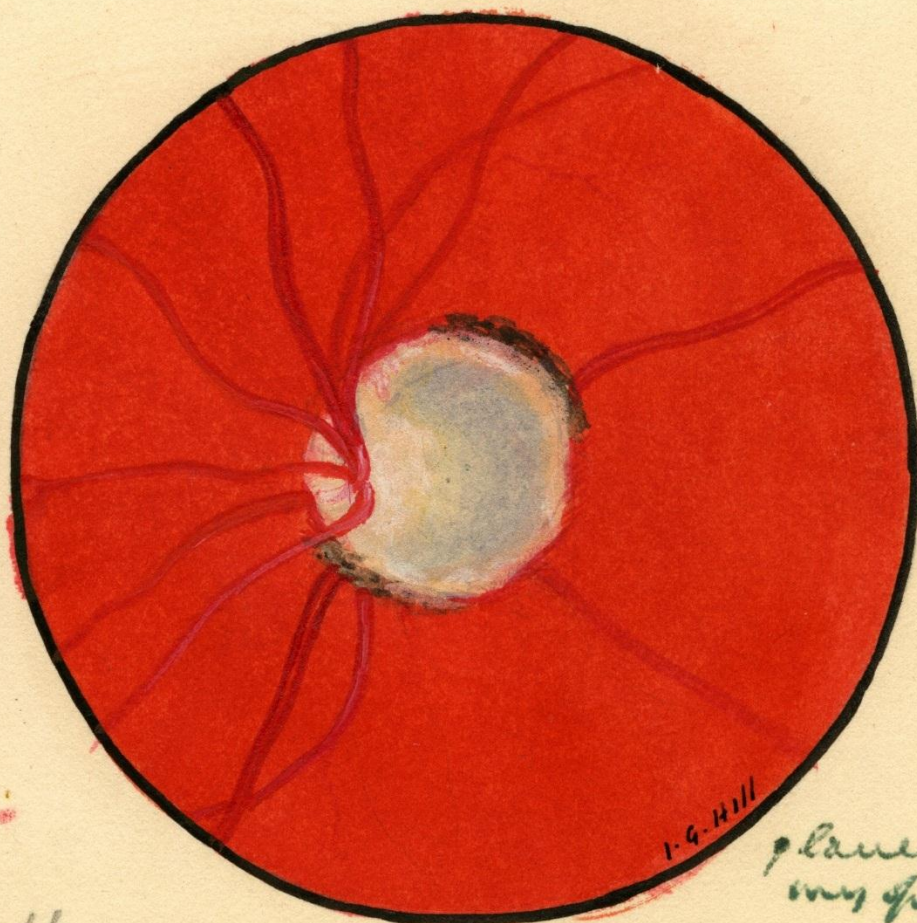


R

I.G. Hill

Myopia atrophy
Glaucoma myopic

W. Swift
M.D.



I.G. Hill

Glaucoma
myopic

57 yrs.

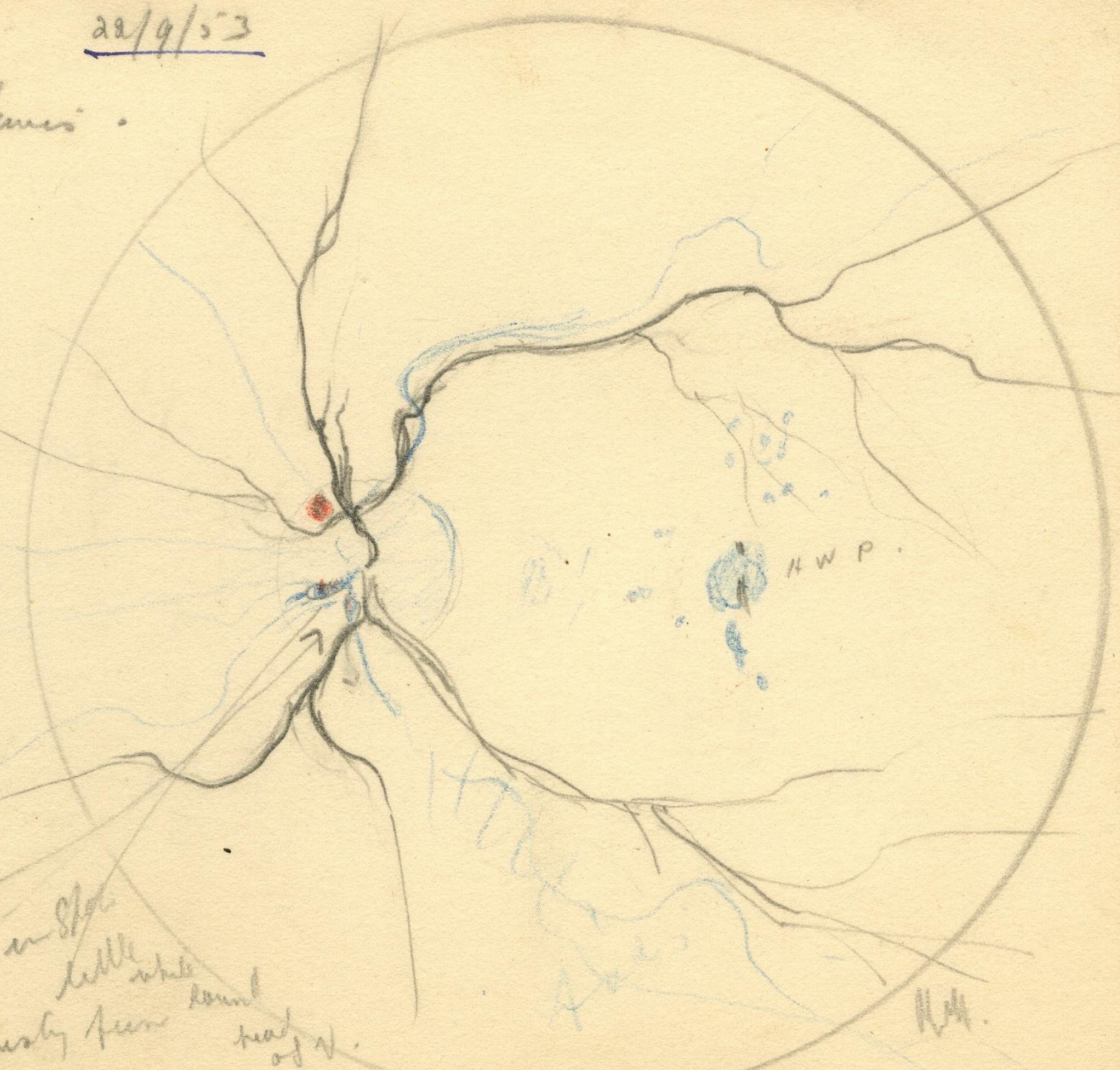
22/9/53

De Lewis.

Done

here
all blurred

very colorful
in outlines
fade out in spots
very much from
little white
round
head of V.

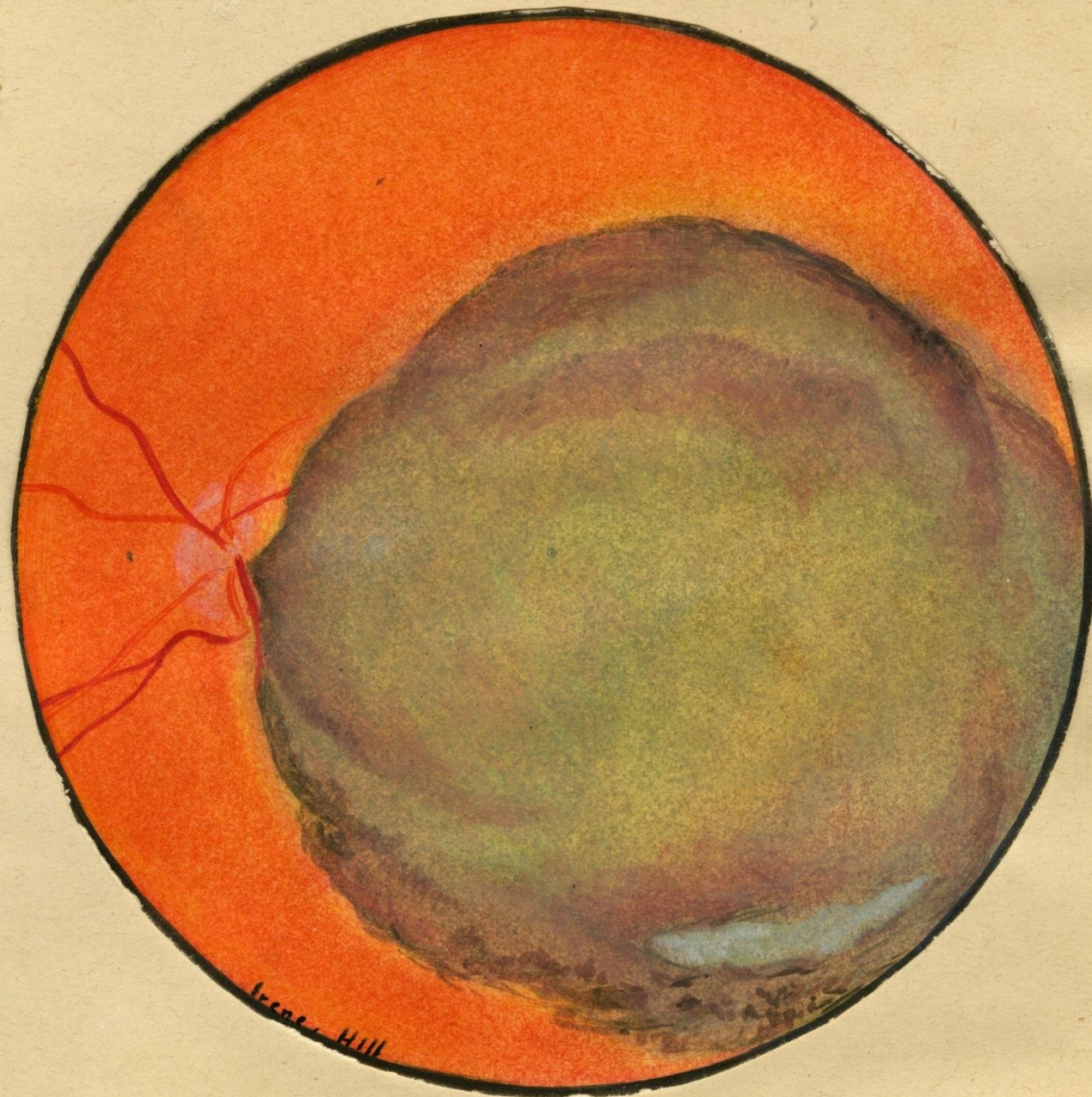


11/4.

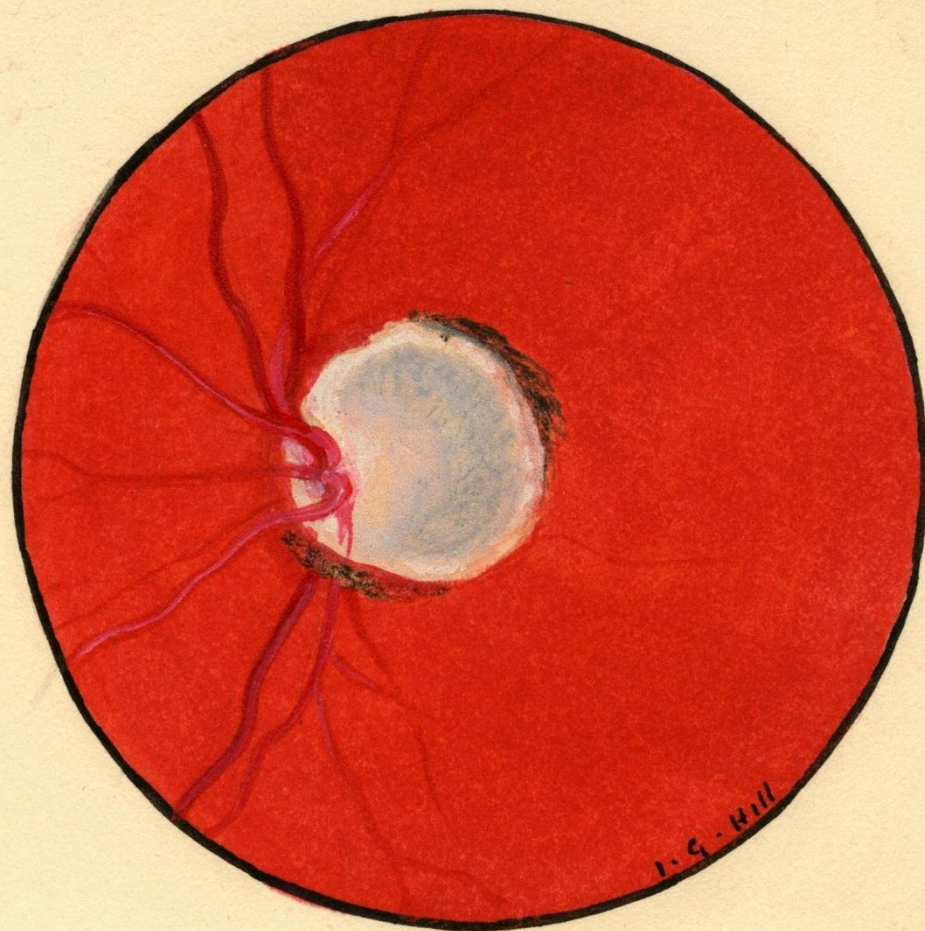
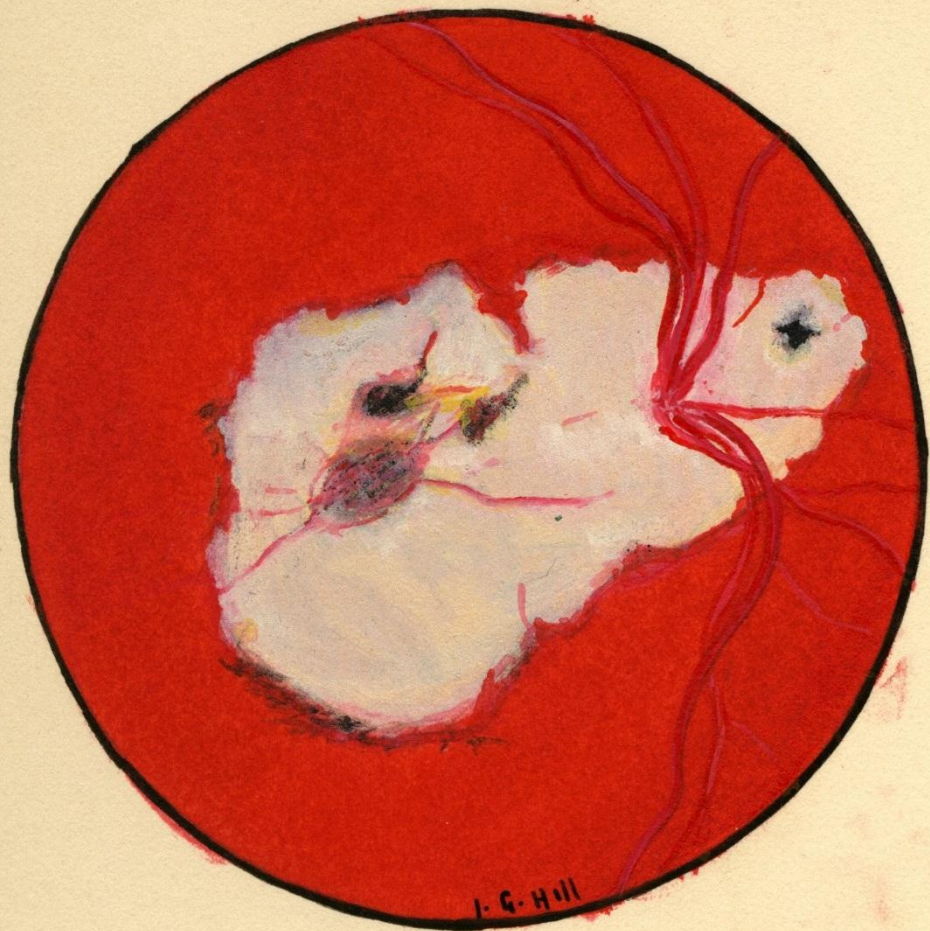
Choroidal Sarcoma
eye excised 28/10/50.



29

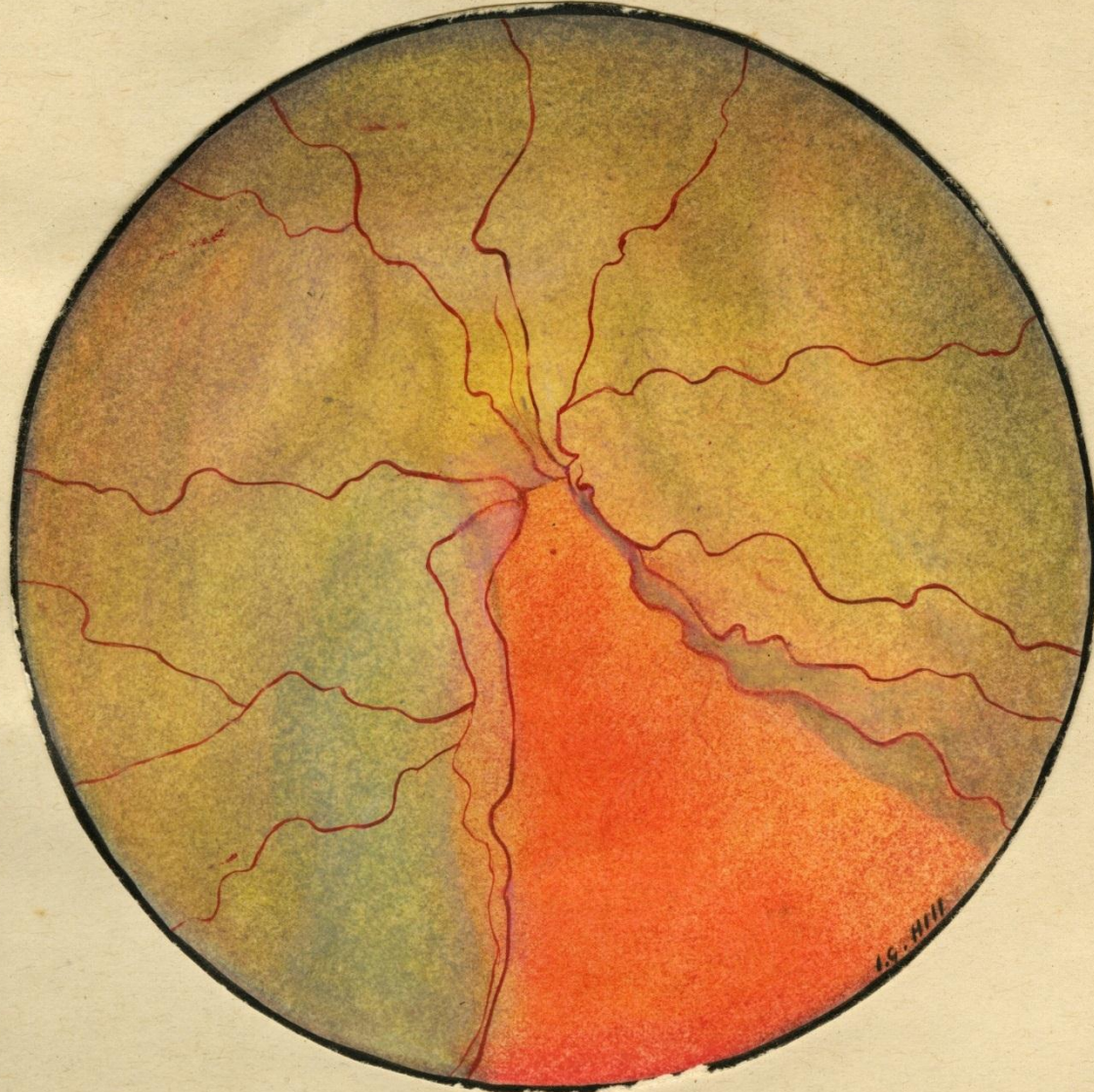


Irene Hill



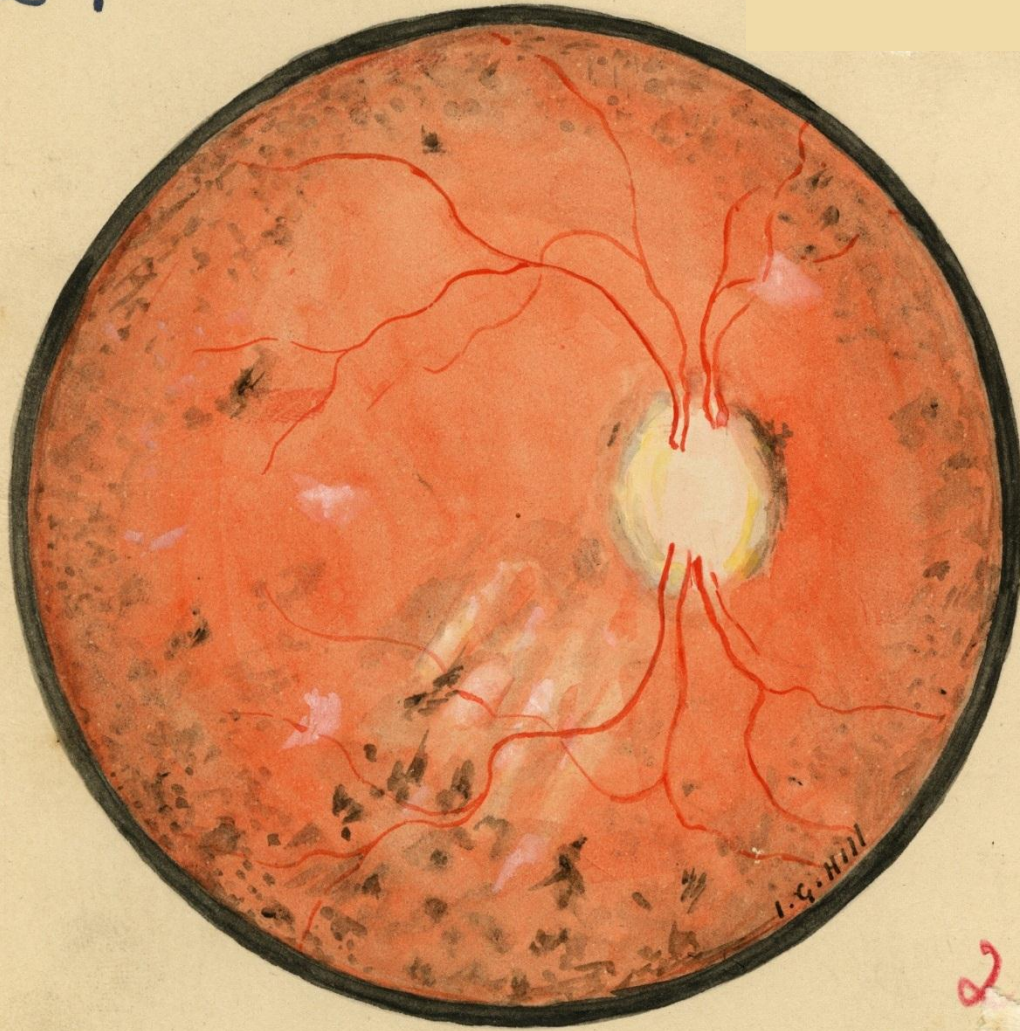
Mr Swift
to R. E.

4 operations for detached retina.
almost complete detachment.

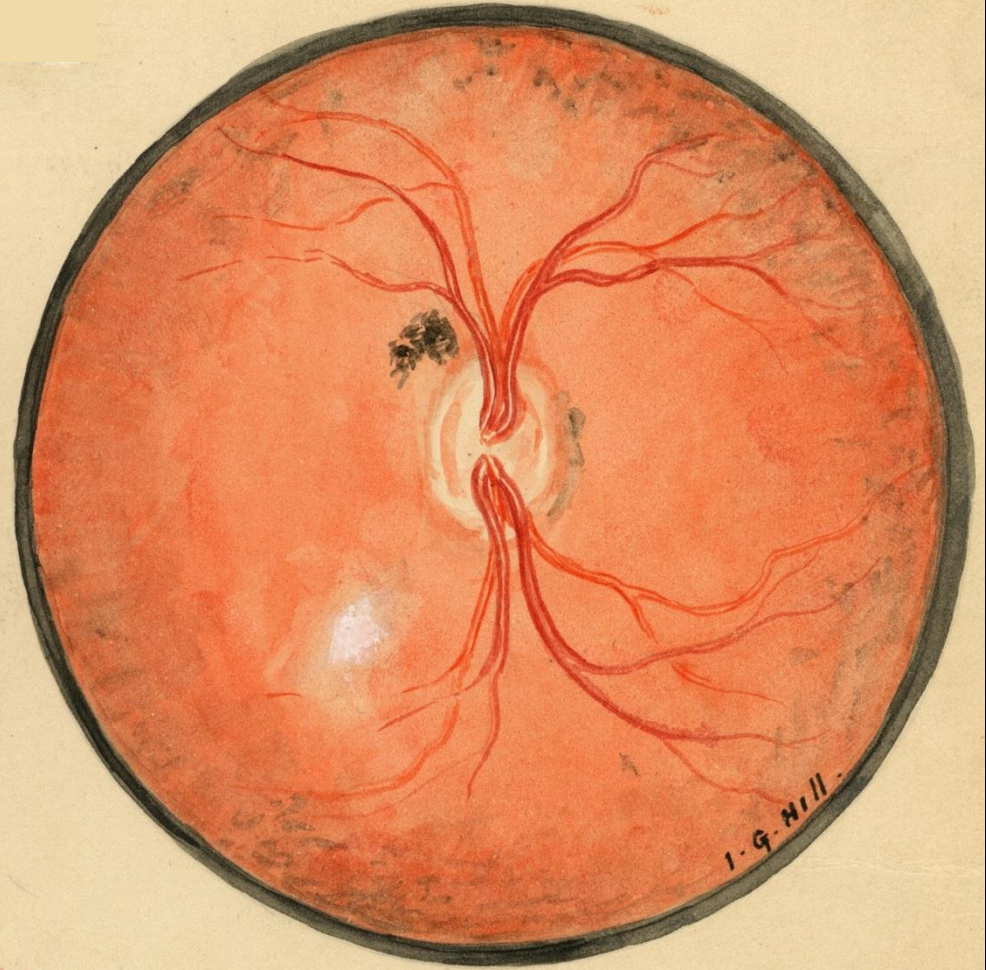


6-20

29



Right fundus



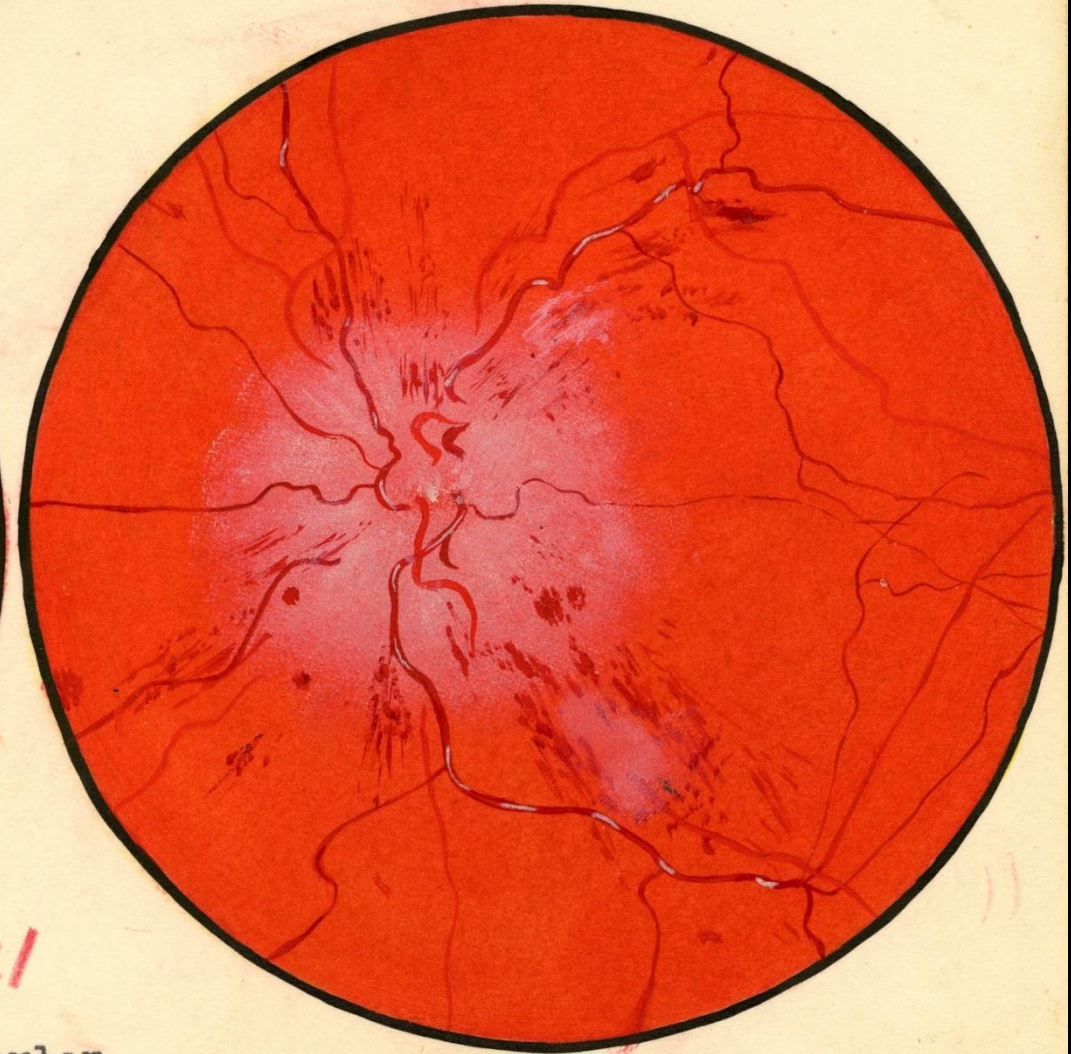
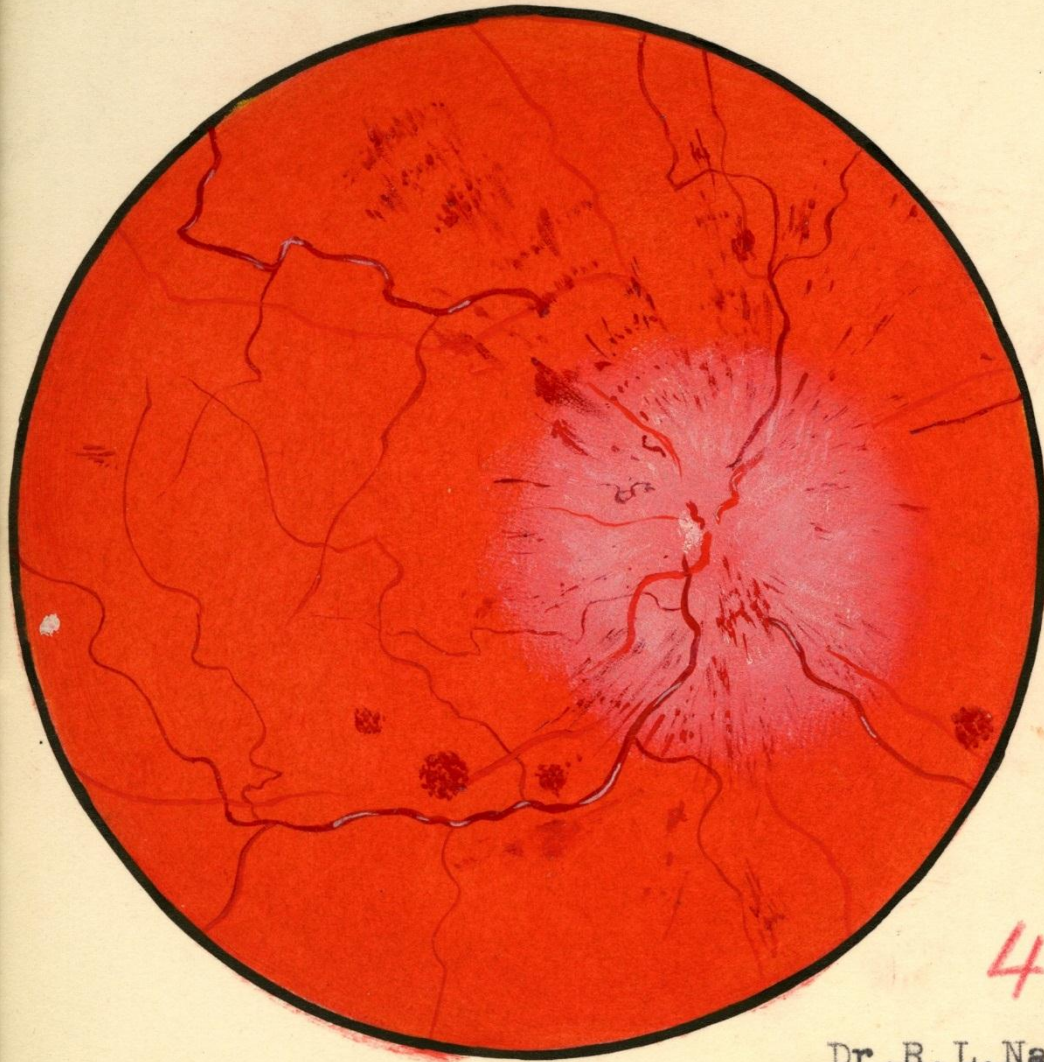
Left fundus

5-10-49

24

MI
58 years.

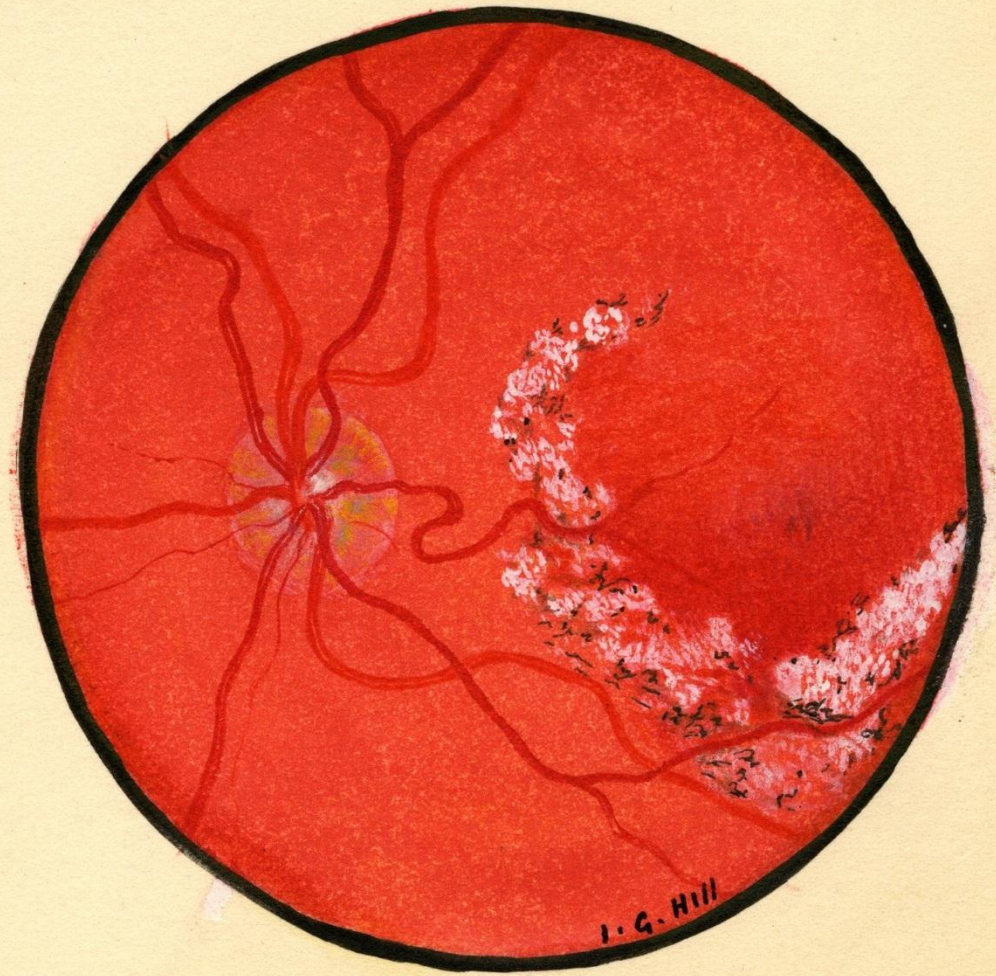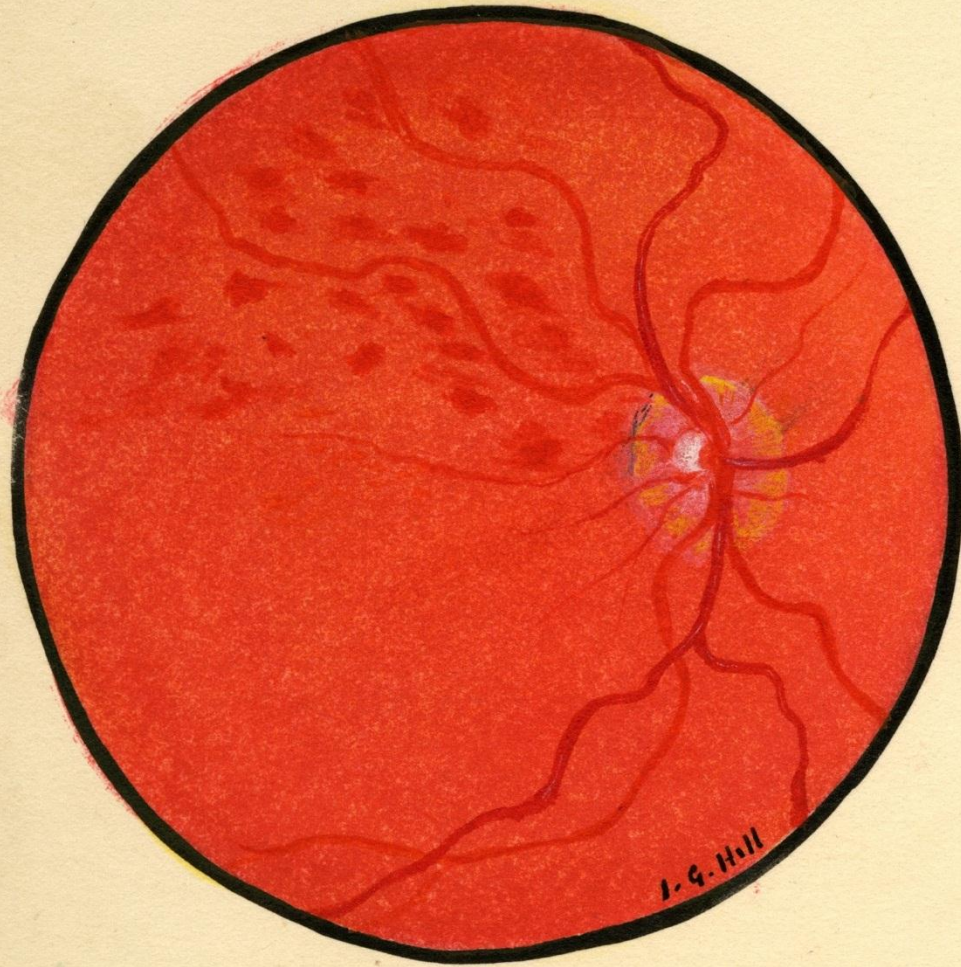
4/6/52.



41

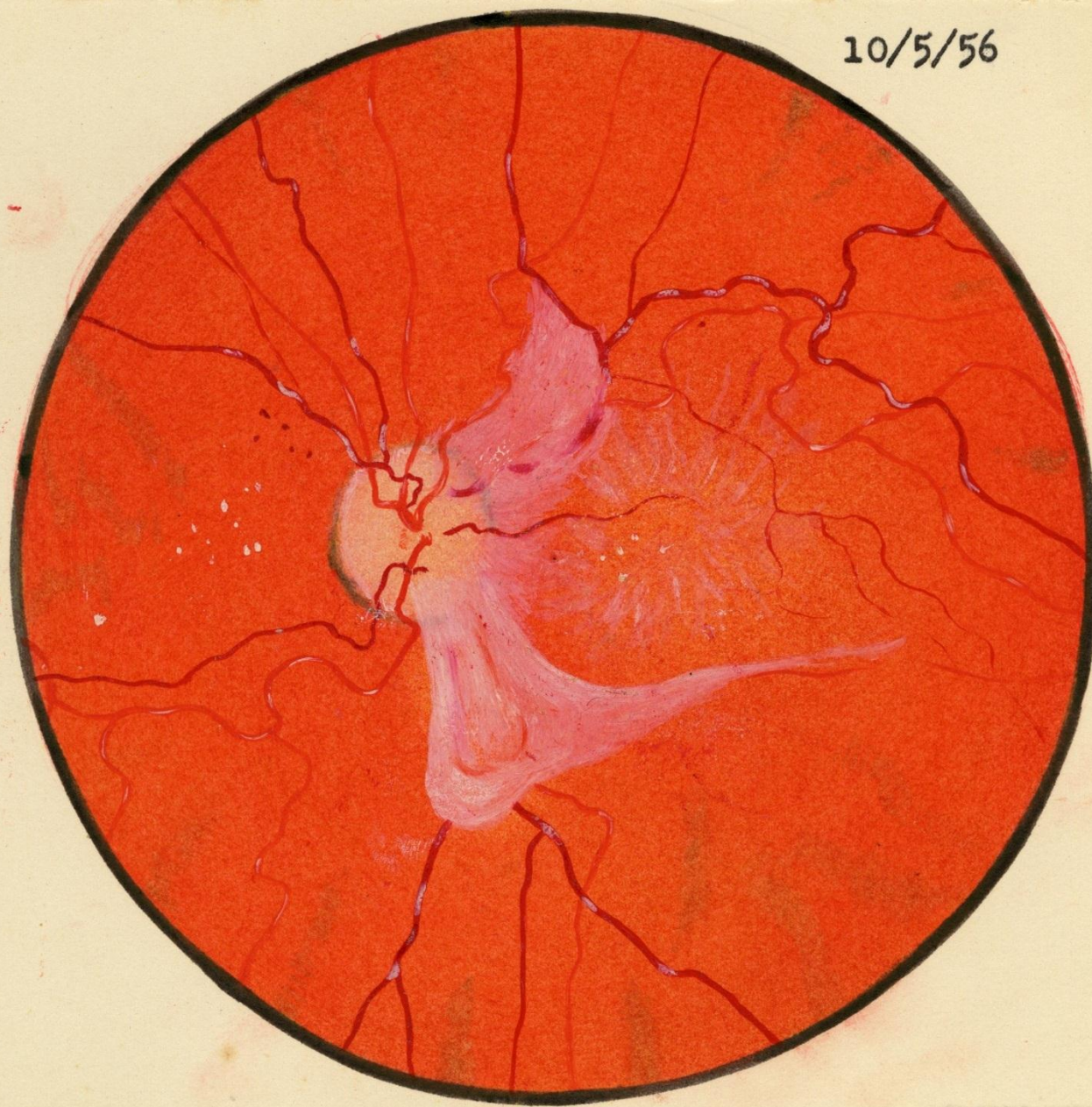
Dr. R. L. Naylor

CIRCINATA RETINITIS.



Circinata Retinitis

10/5/56



Dr. R. L. Naylor.

MR

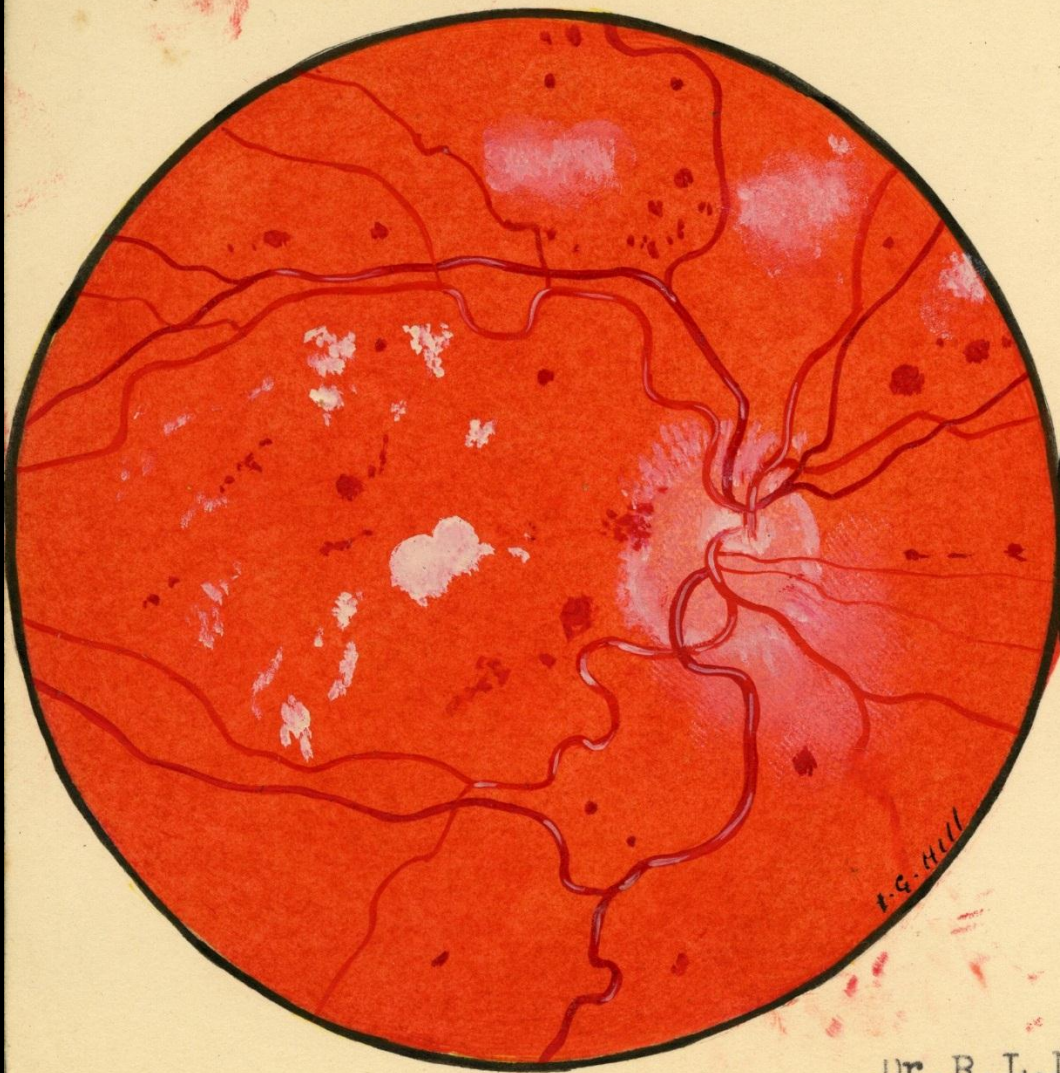
70 yrs

70 years.

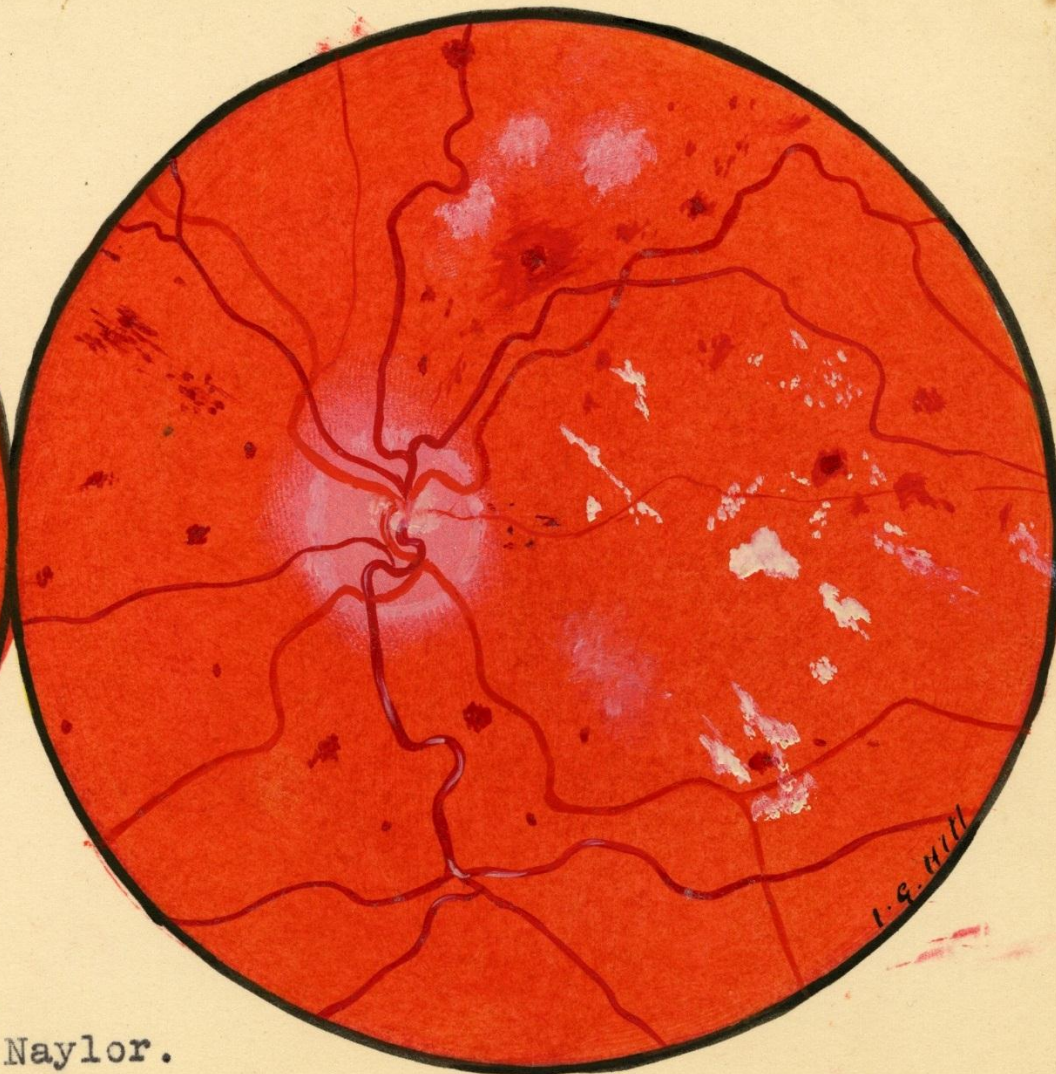
Retinitis

Diabetic Retinitis.

7/8/53.



I.G. Hill



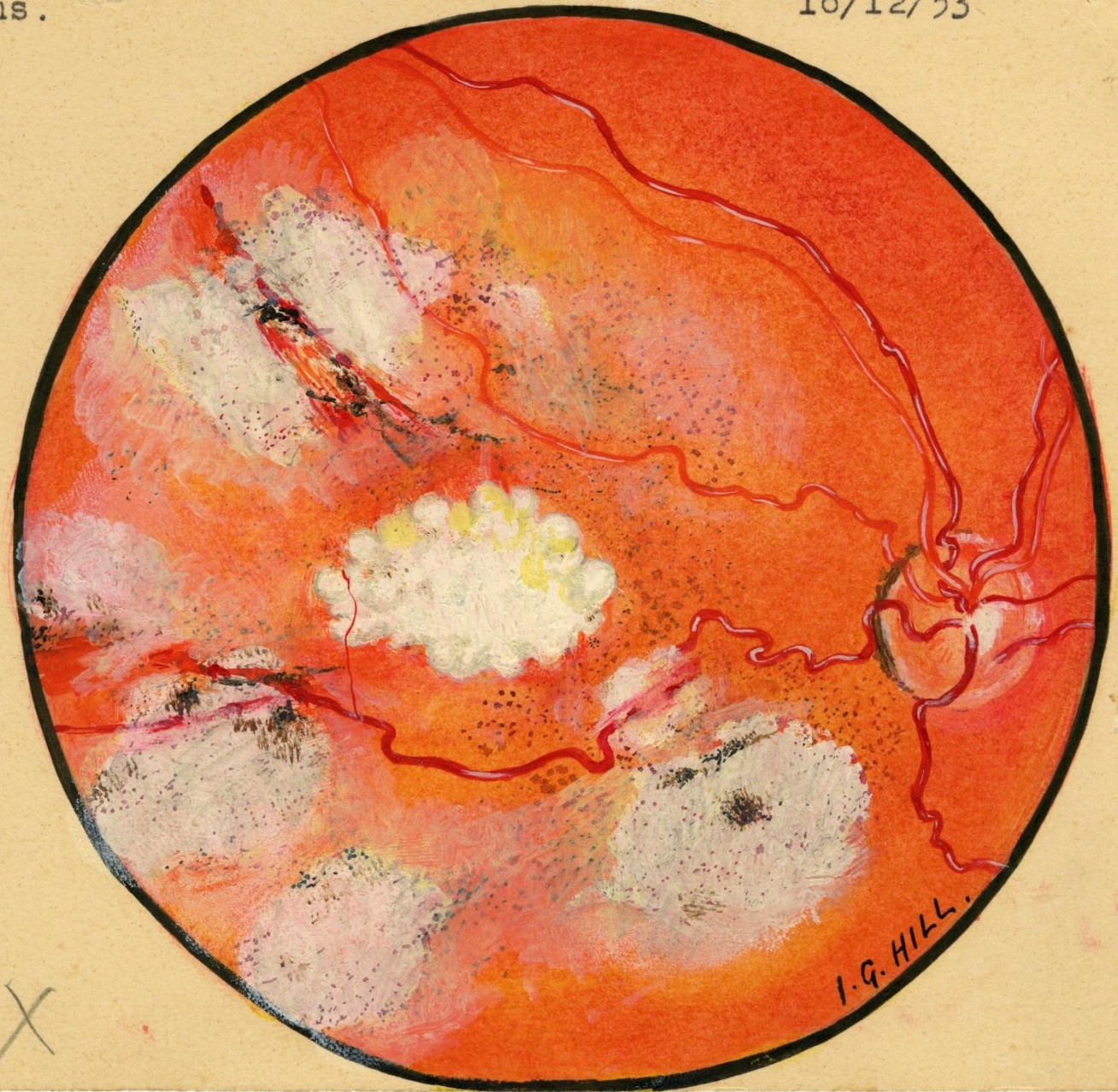
I.G. Hill

Dr. R. L. Naylor.

DR. R. L. Naylor

17months.

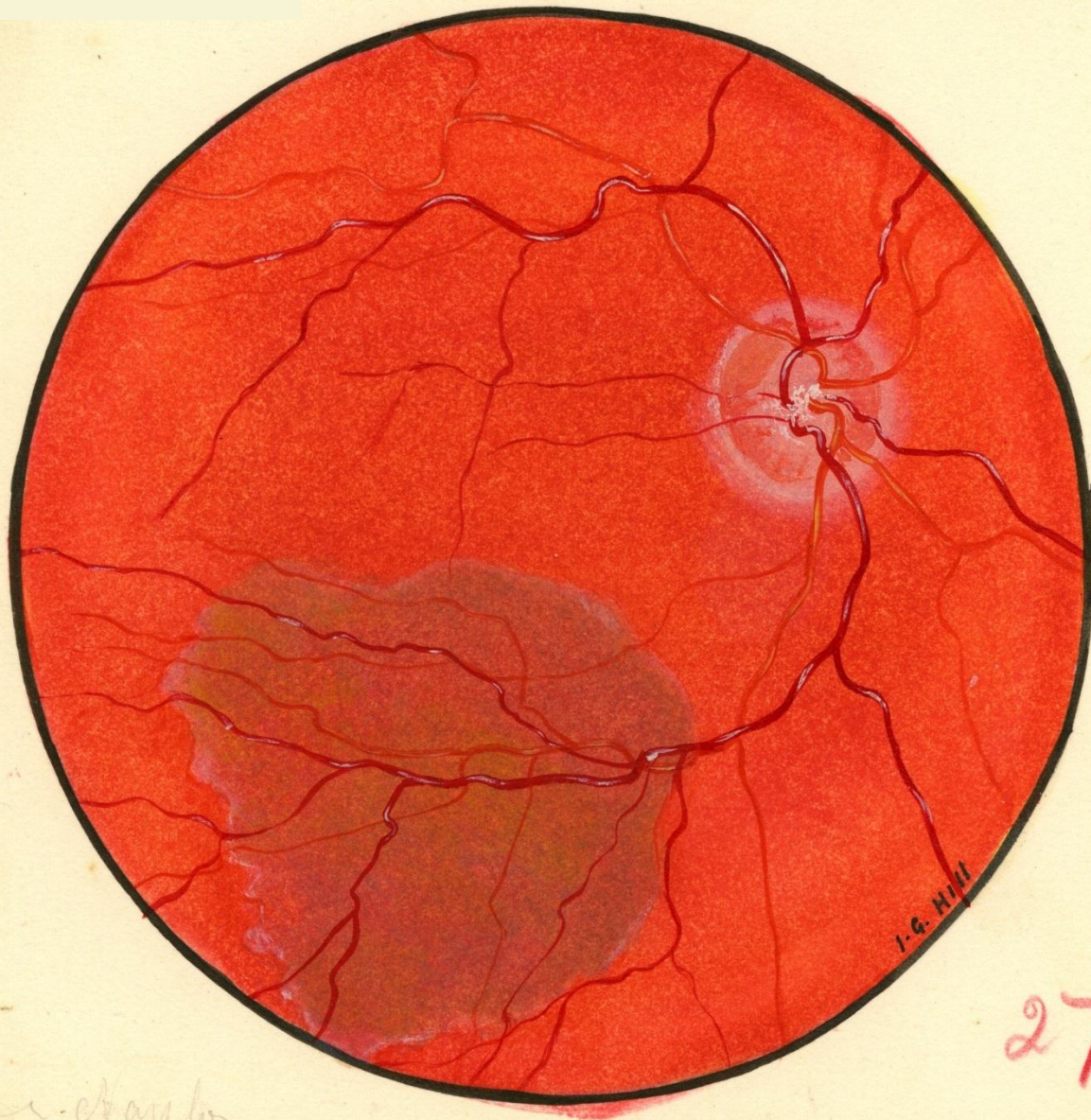
16/12/53



Dr. Joyce

X

4/4/51.



I.G. Hill

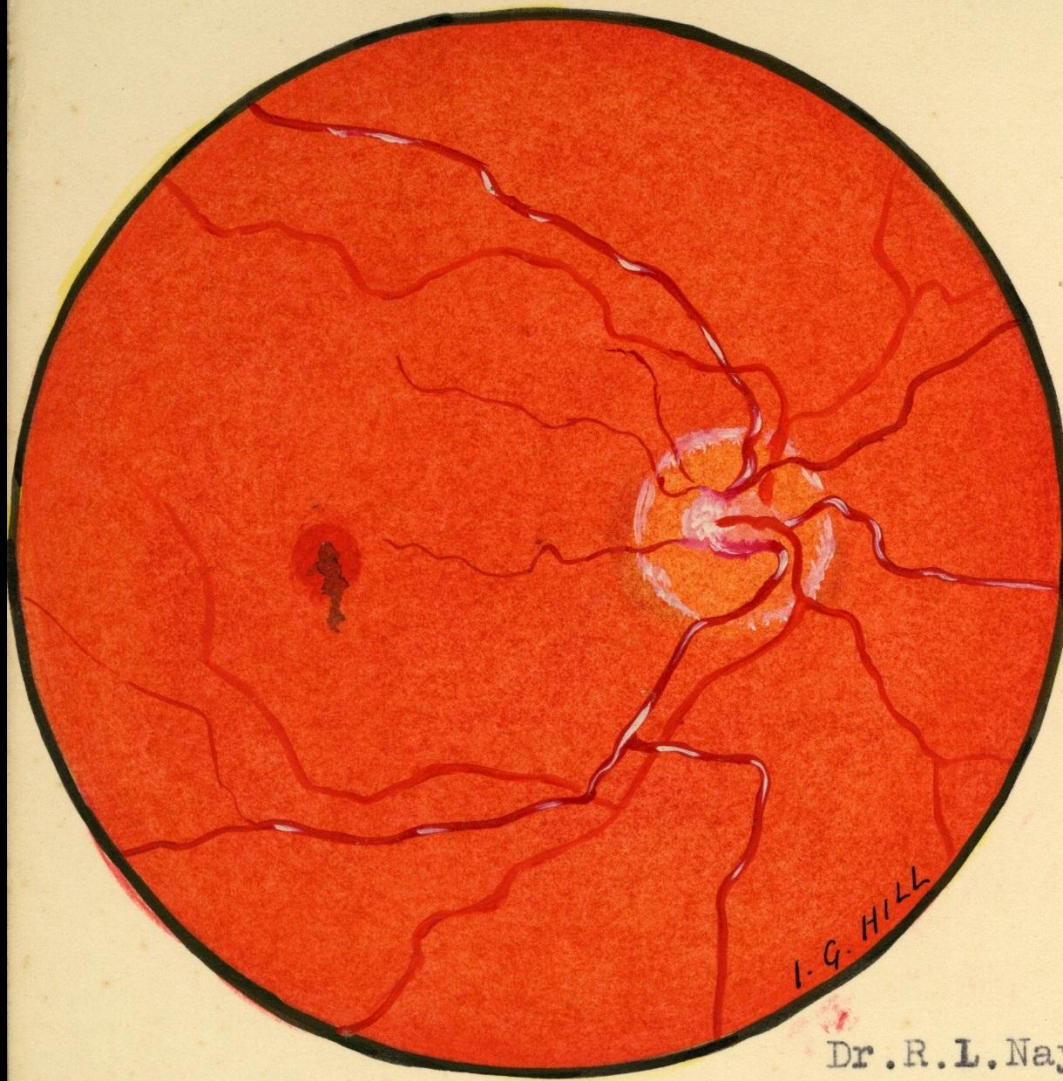
27 A

Dr. R.L. Naylor.

Dr. Naylor

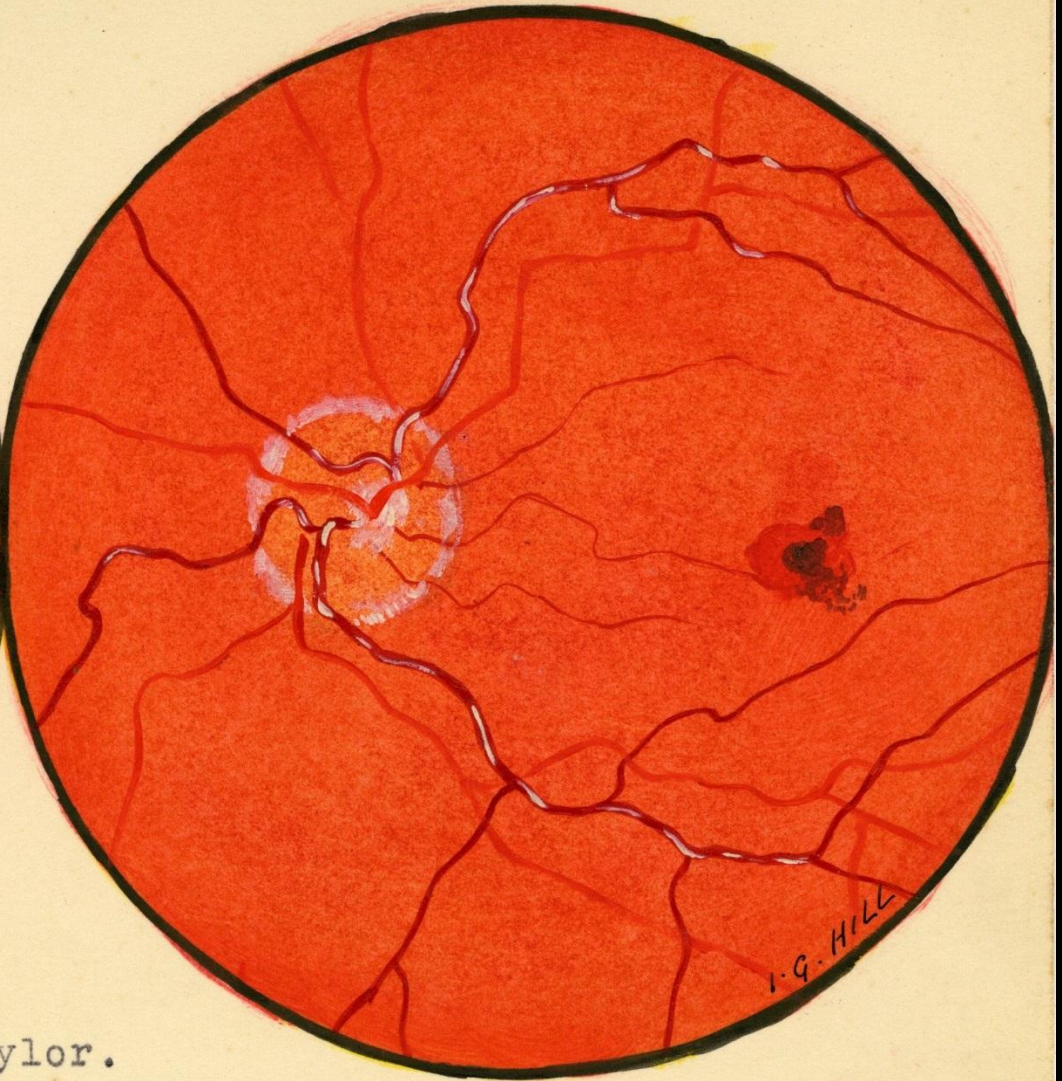
Macula degeneration.

6/4/54.



I. G. HILL

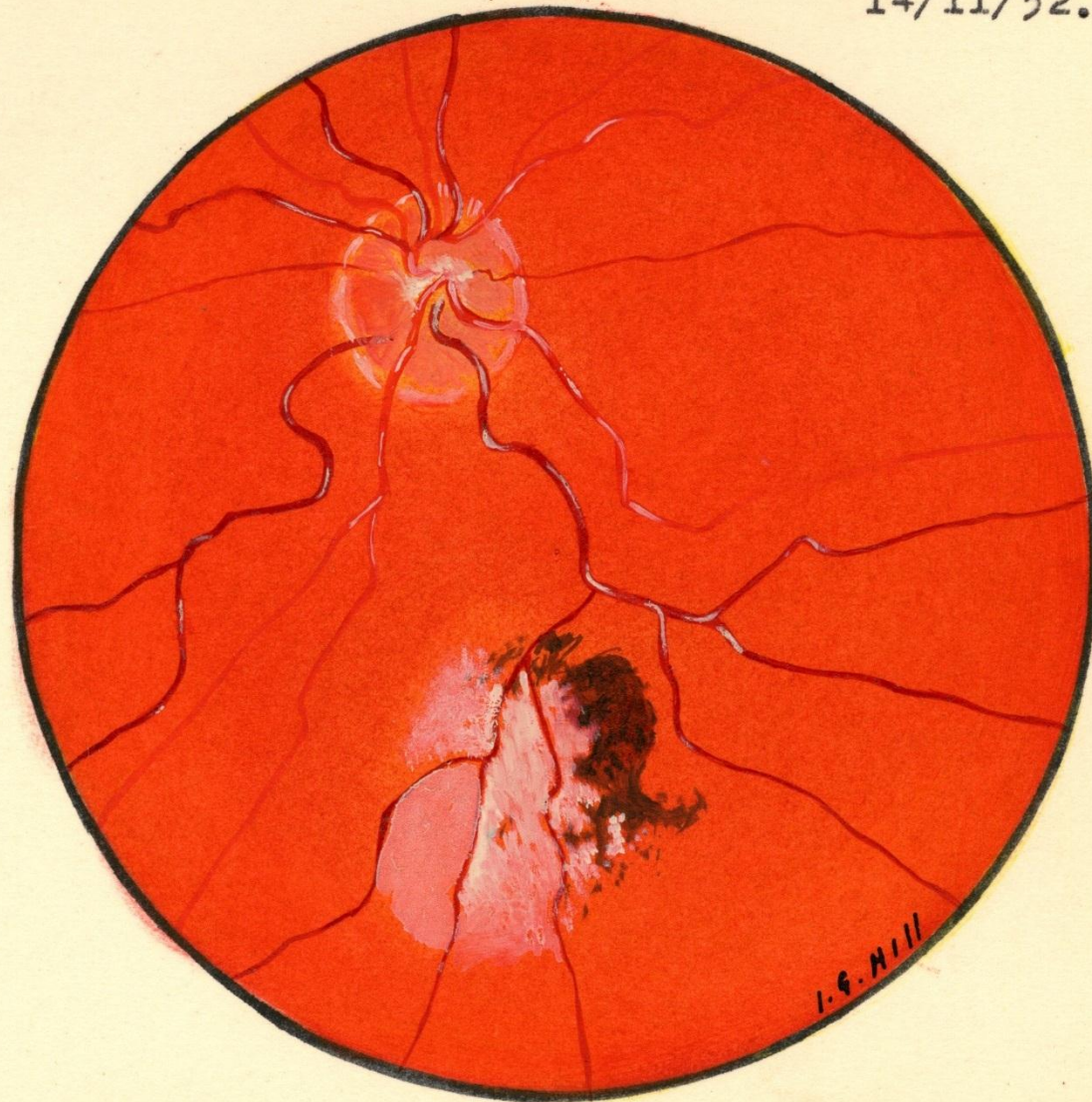
Dr. R. L. Naylor.



I. G. HILL

22years

14/11/52.

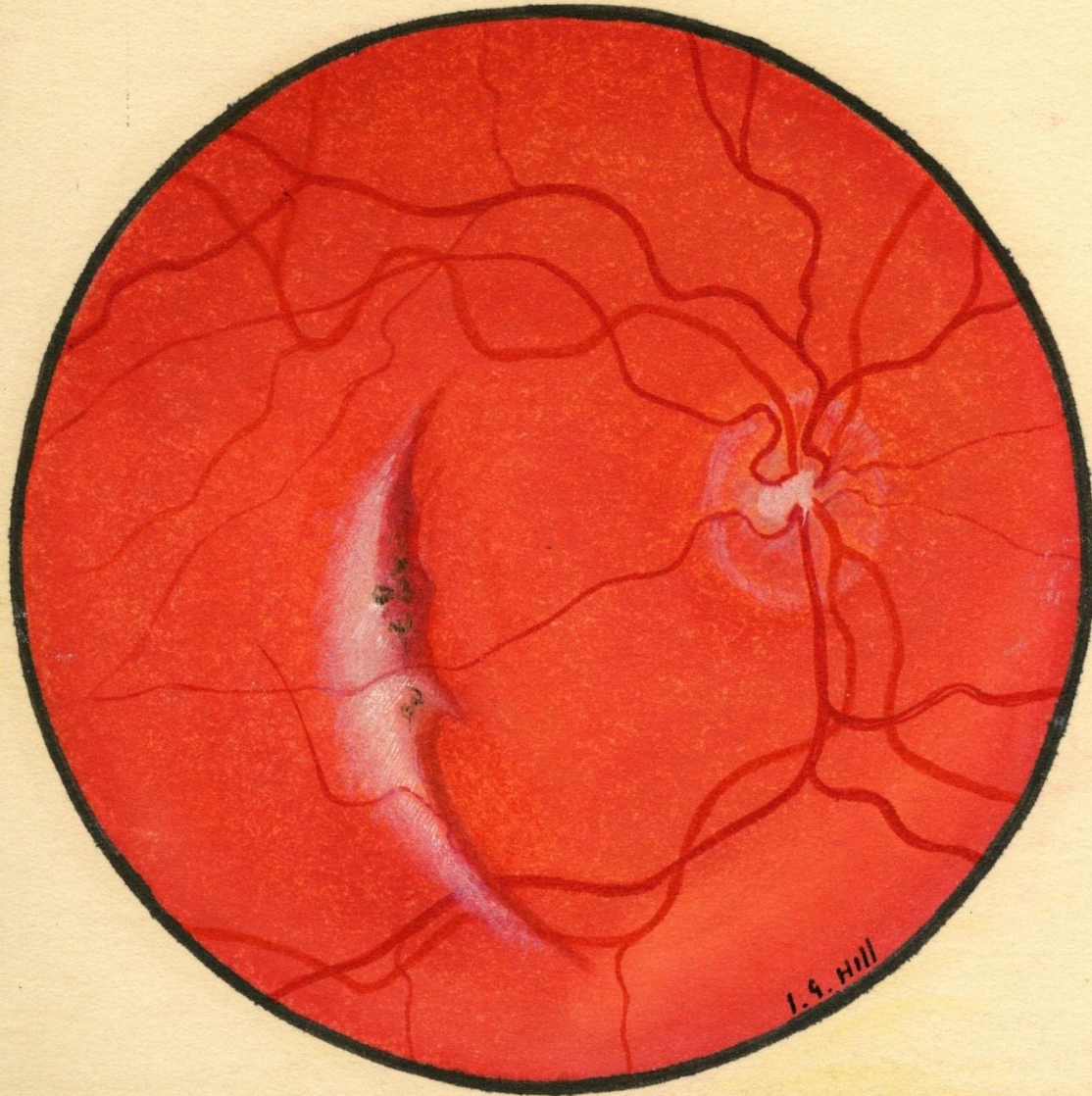


Dr. R.L.Naylor.

I.G.Hill

Ruptured Choroid.

23/6/50.



L.S. Hill

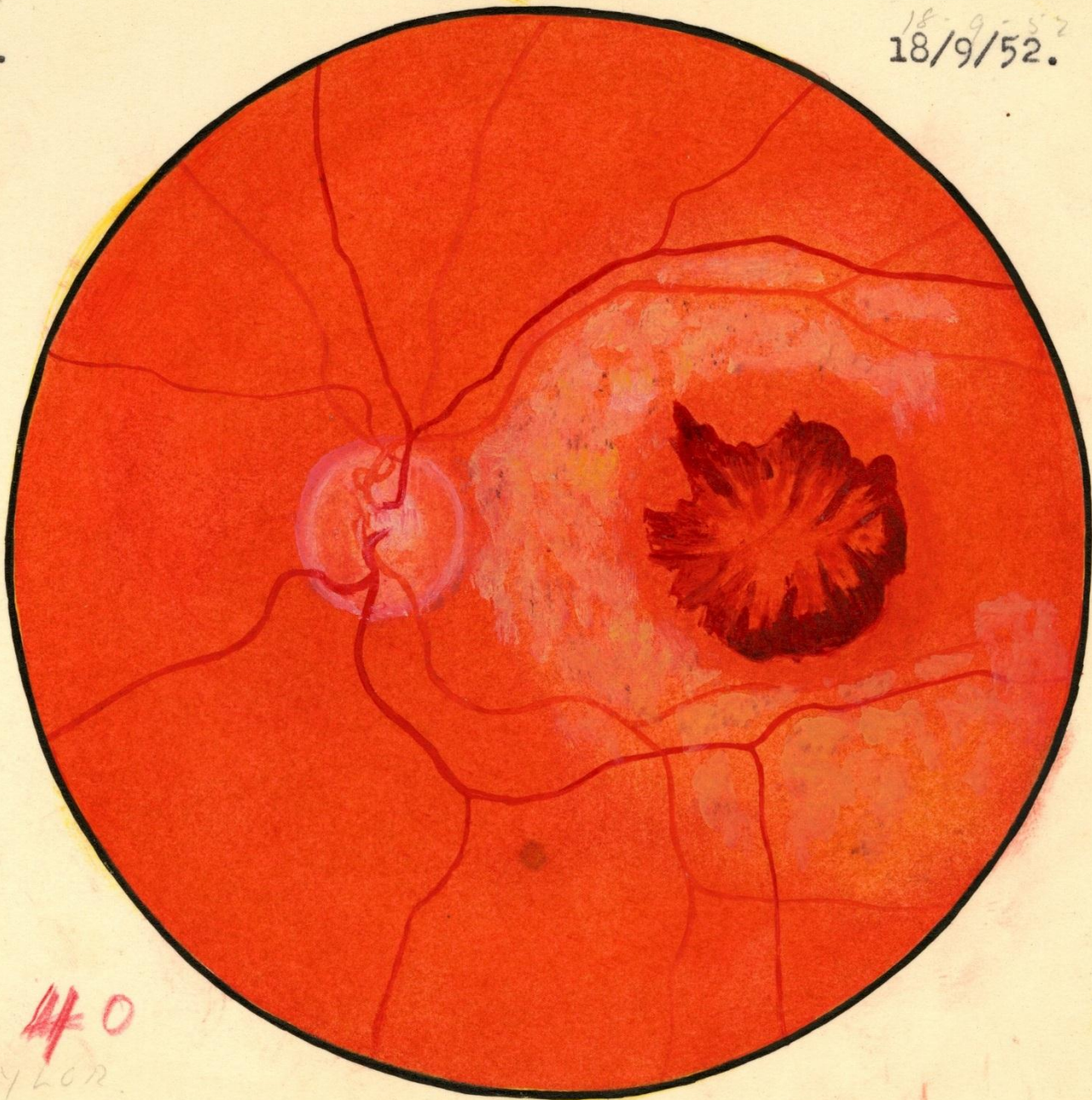
44

R

17

63 years.
63years.

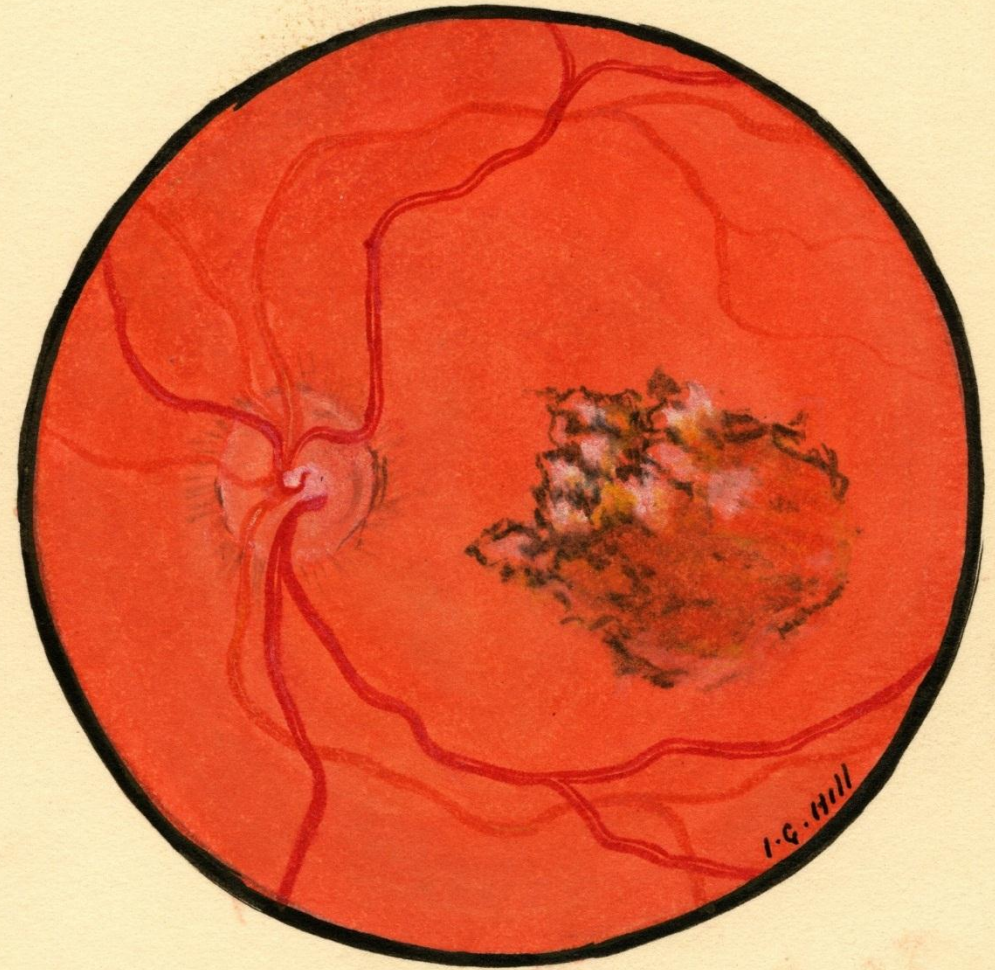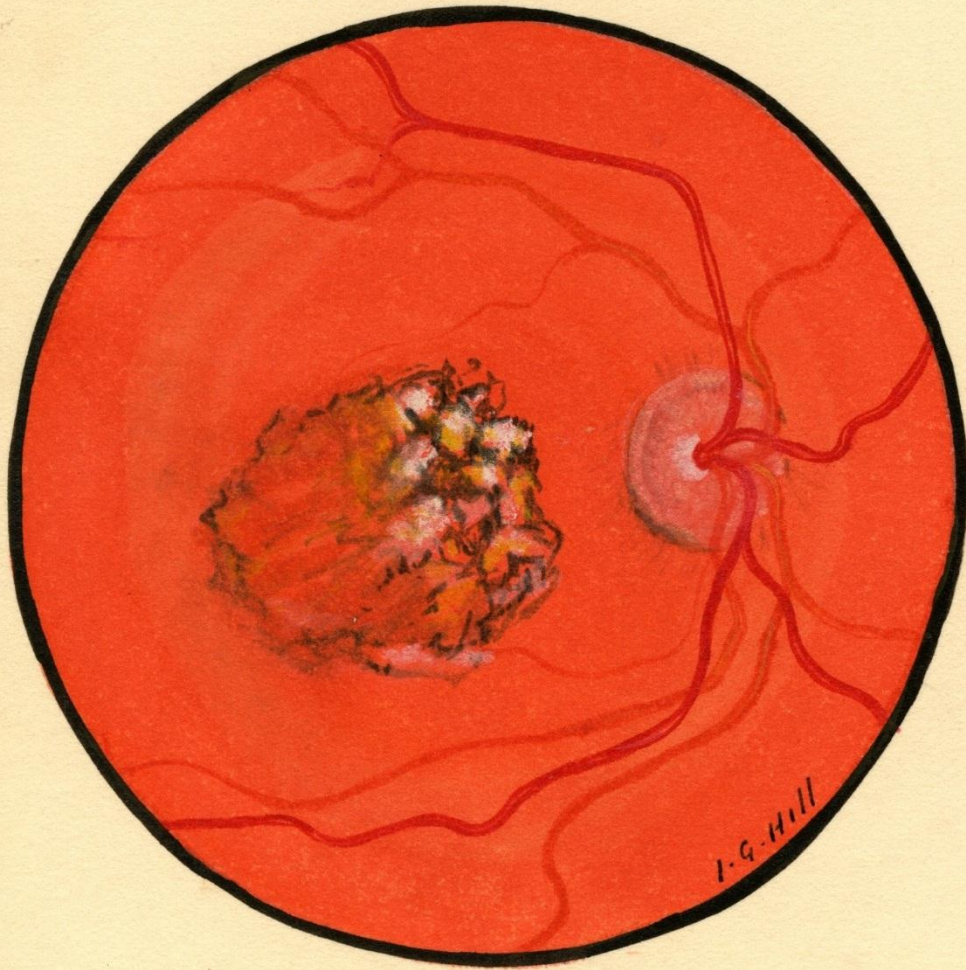
18-9-52
18/9/52.



Dr.R.L.Naylor.

40

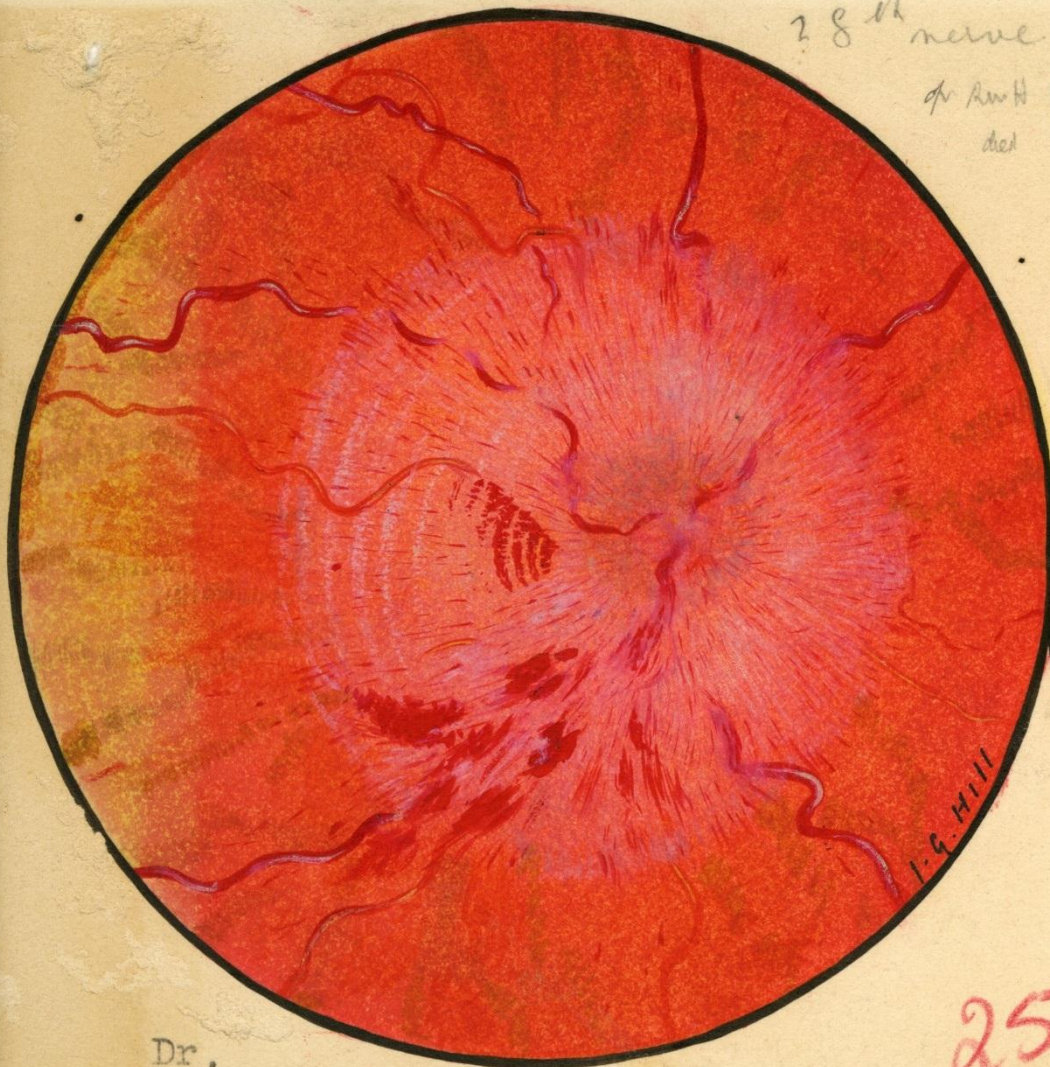DR NAYLOR



Possible audit
28th nerve tumour

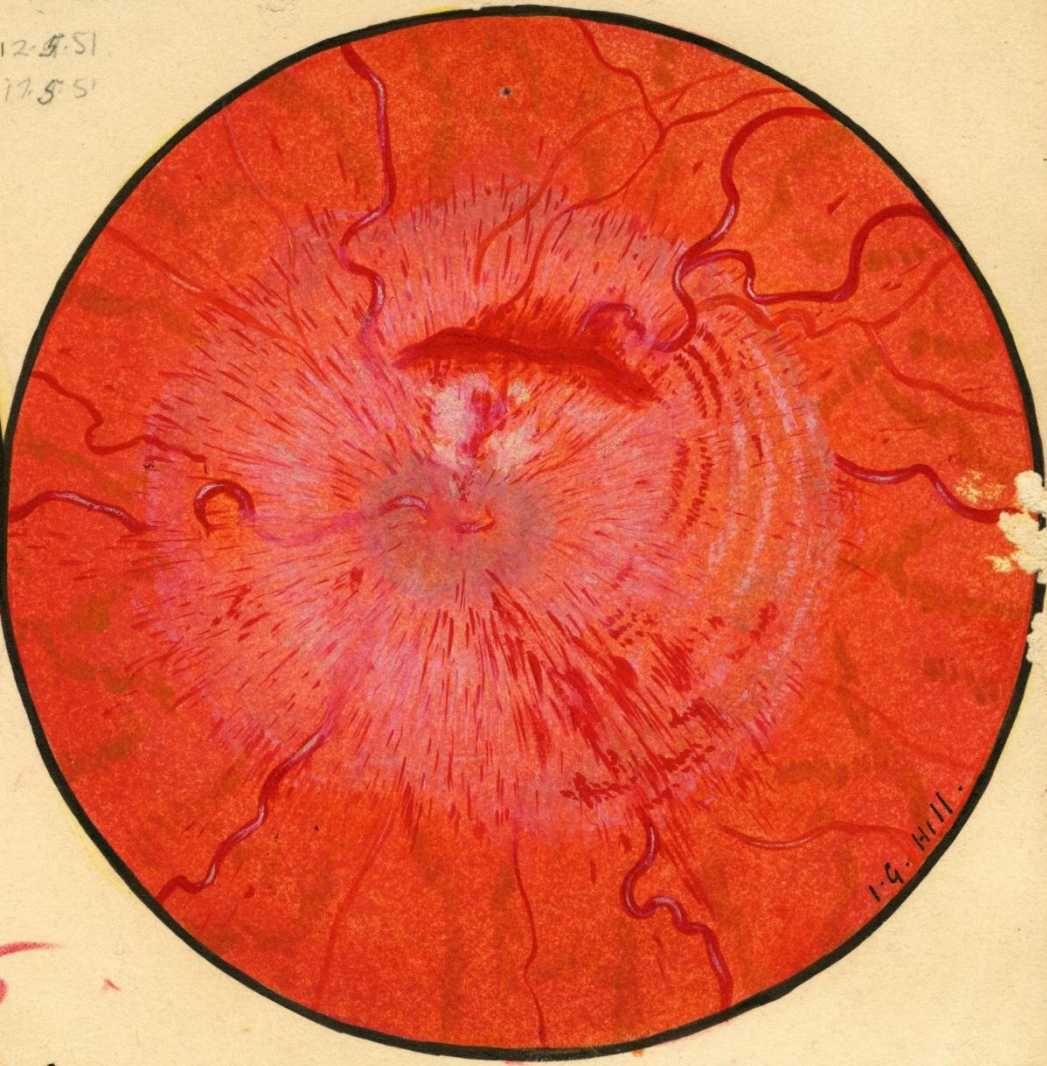
27/4/51.

for RWH 12.5.51
date 17.5.51



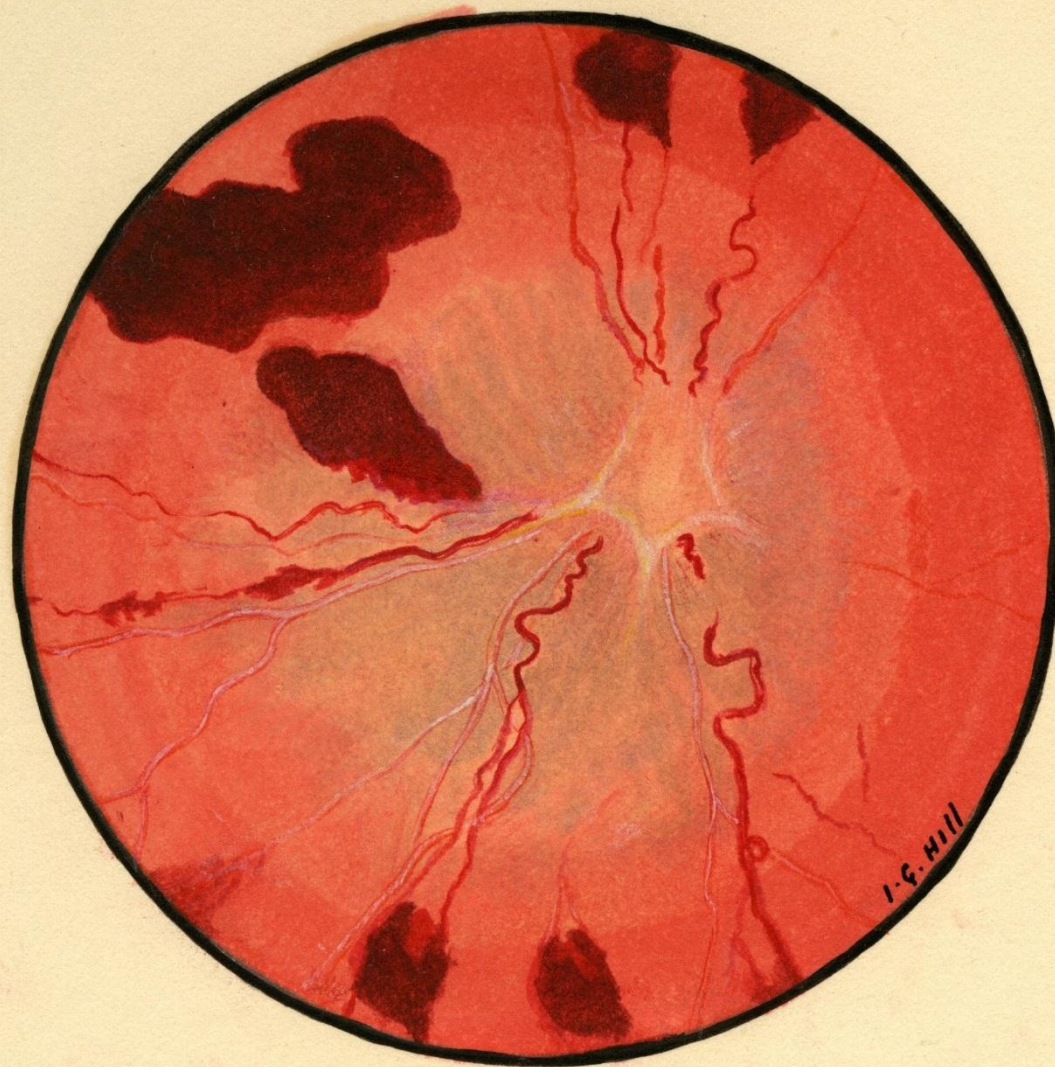
I.G. Hill

25



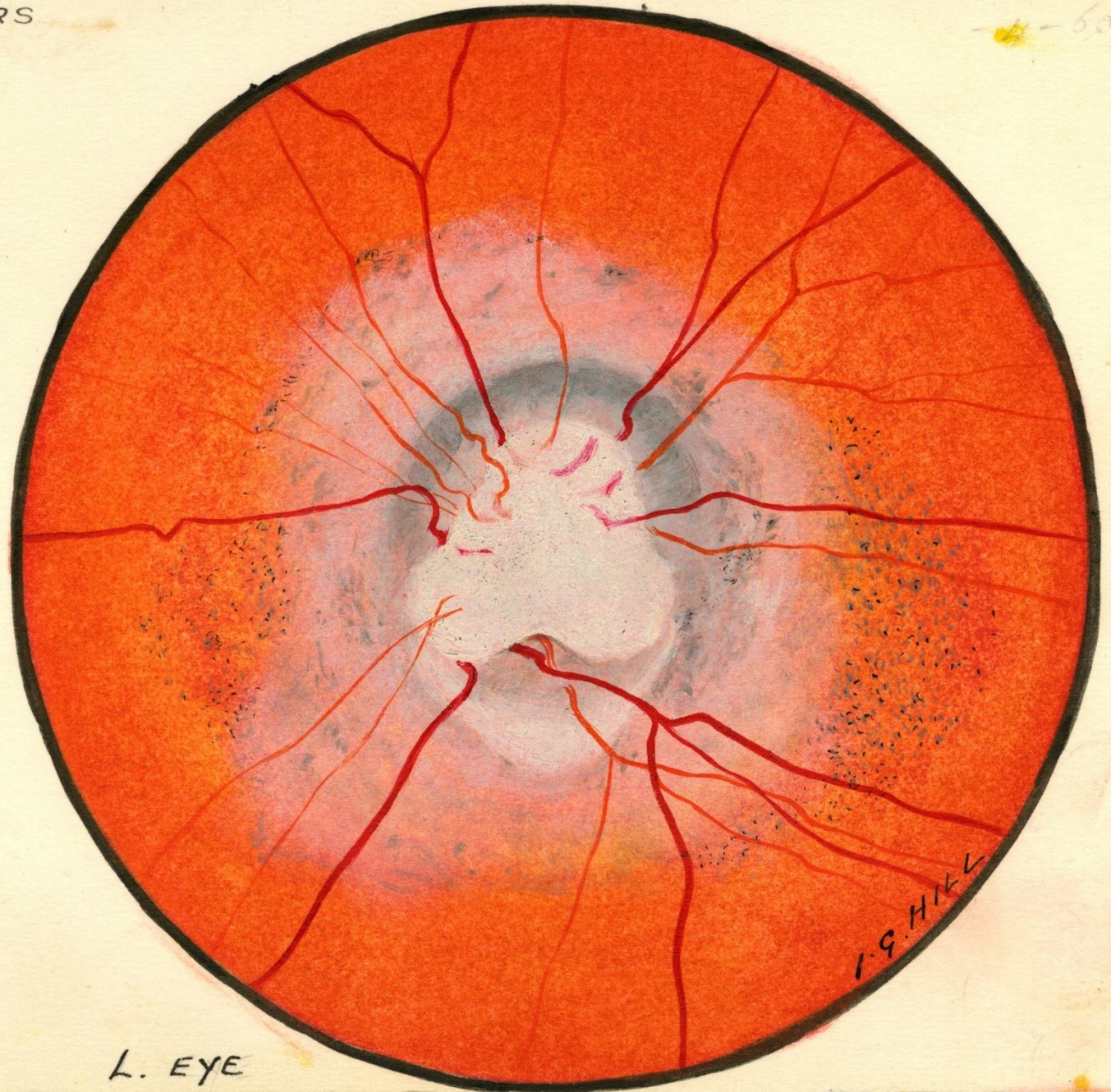
I.G. Hill

Dr.
R.L. Naylor.



1-6-11

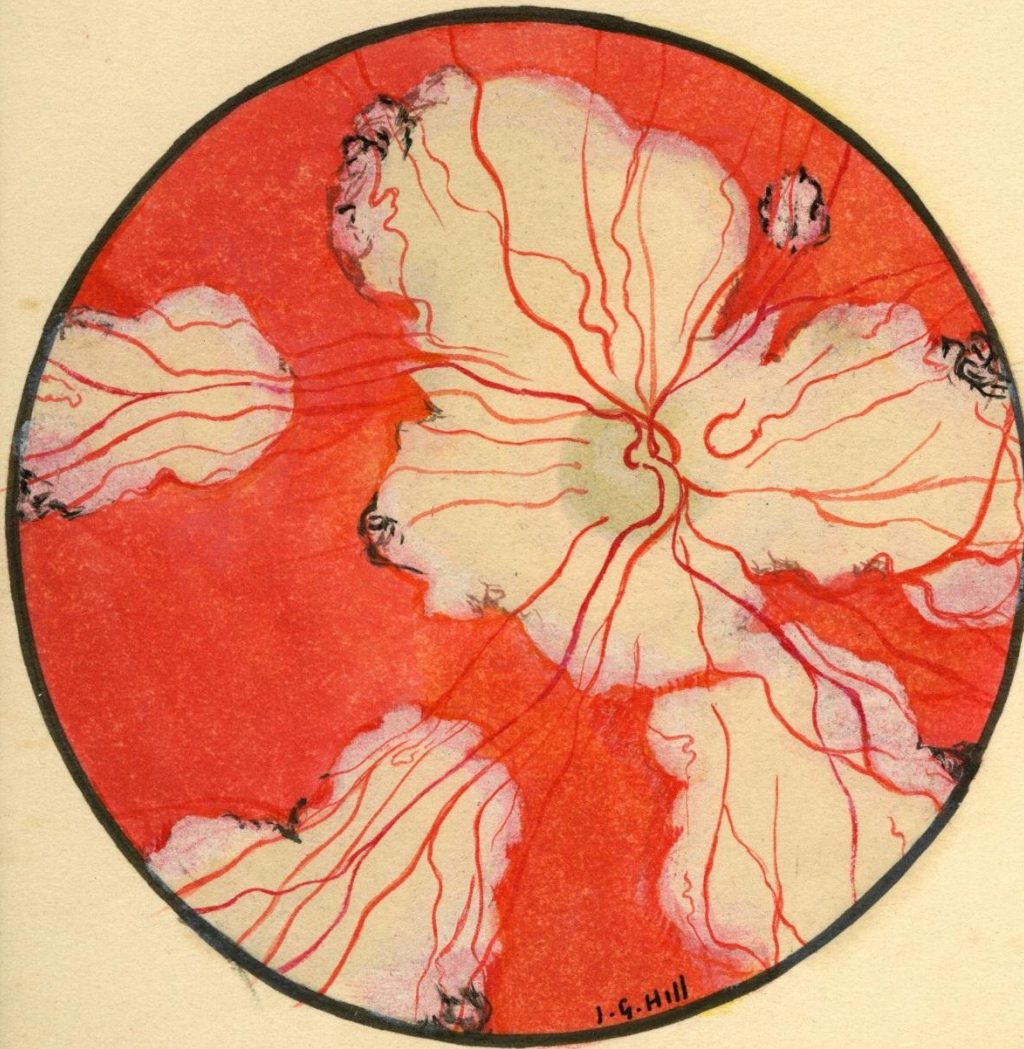
9 YEARS



DR. R. L. NAYLOR

L. EYE

72 yrs. Eye & Ear Hospital. M2447. 26/6/50

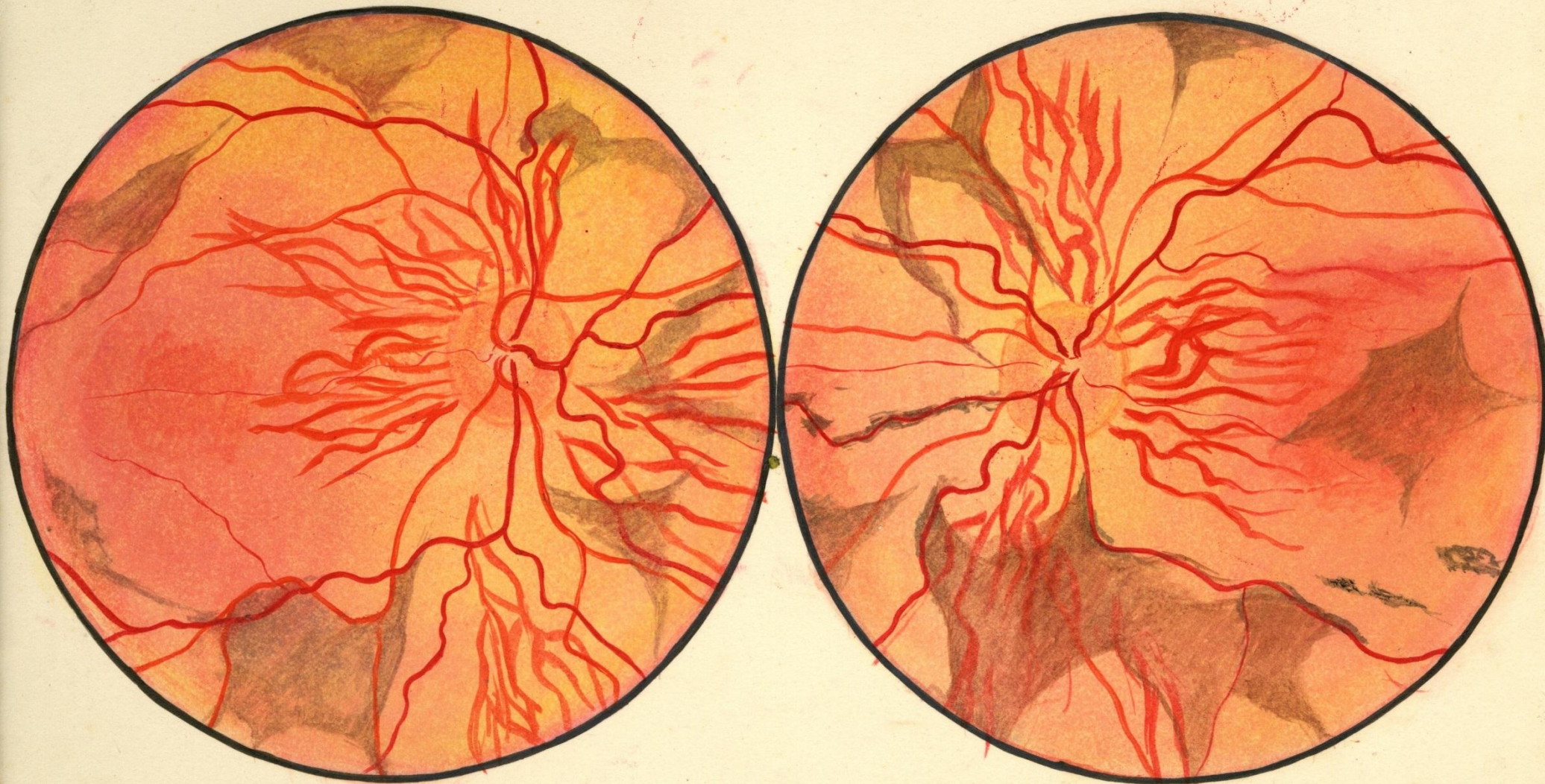

J.G. Hill



J.G. Hill

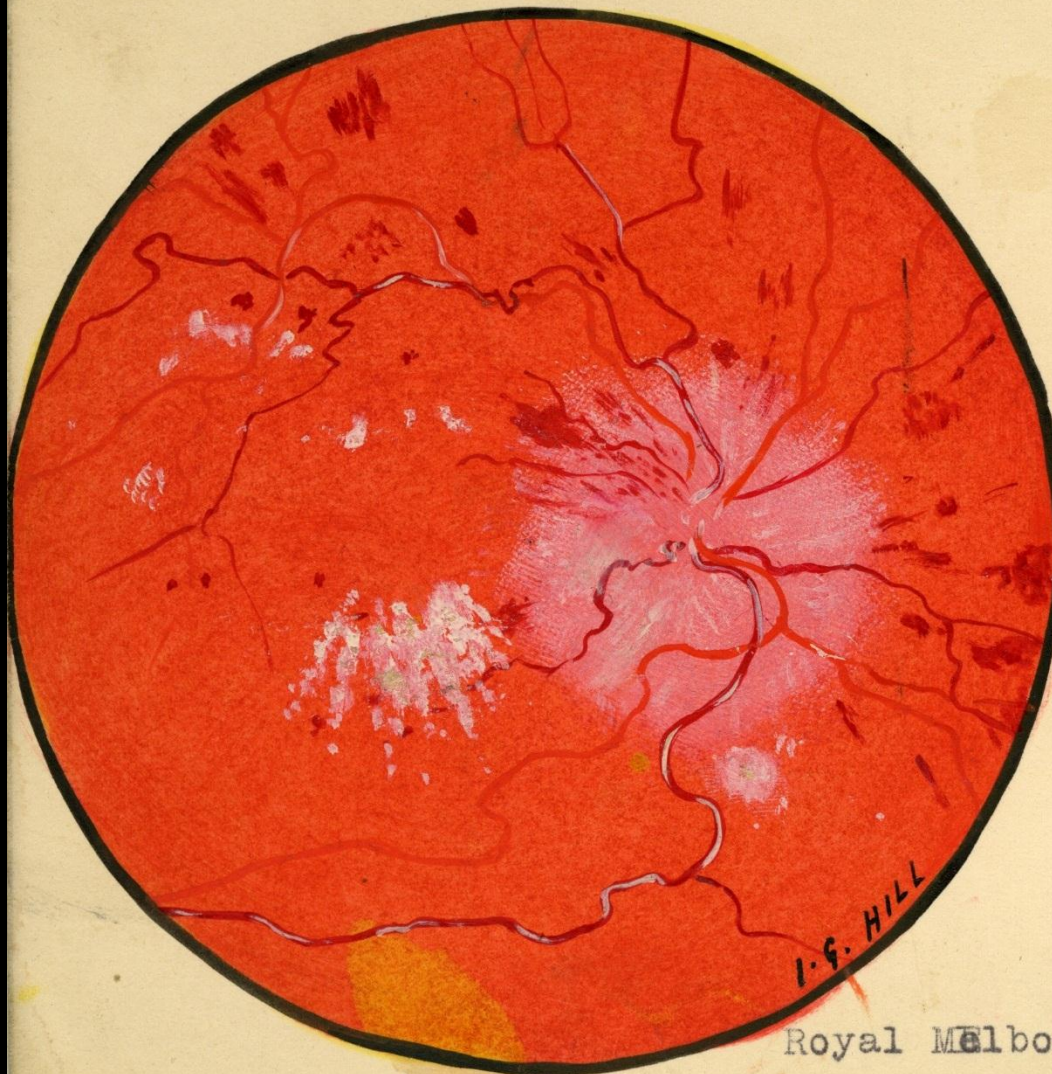3/5/51.



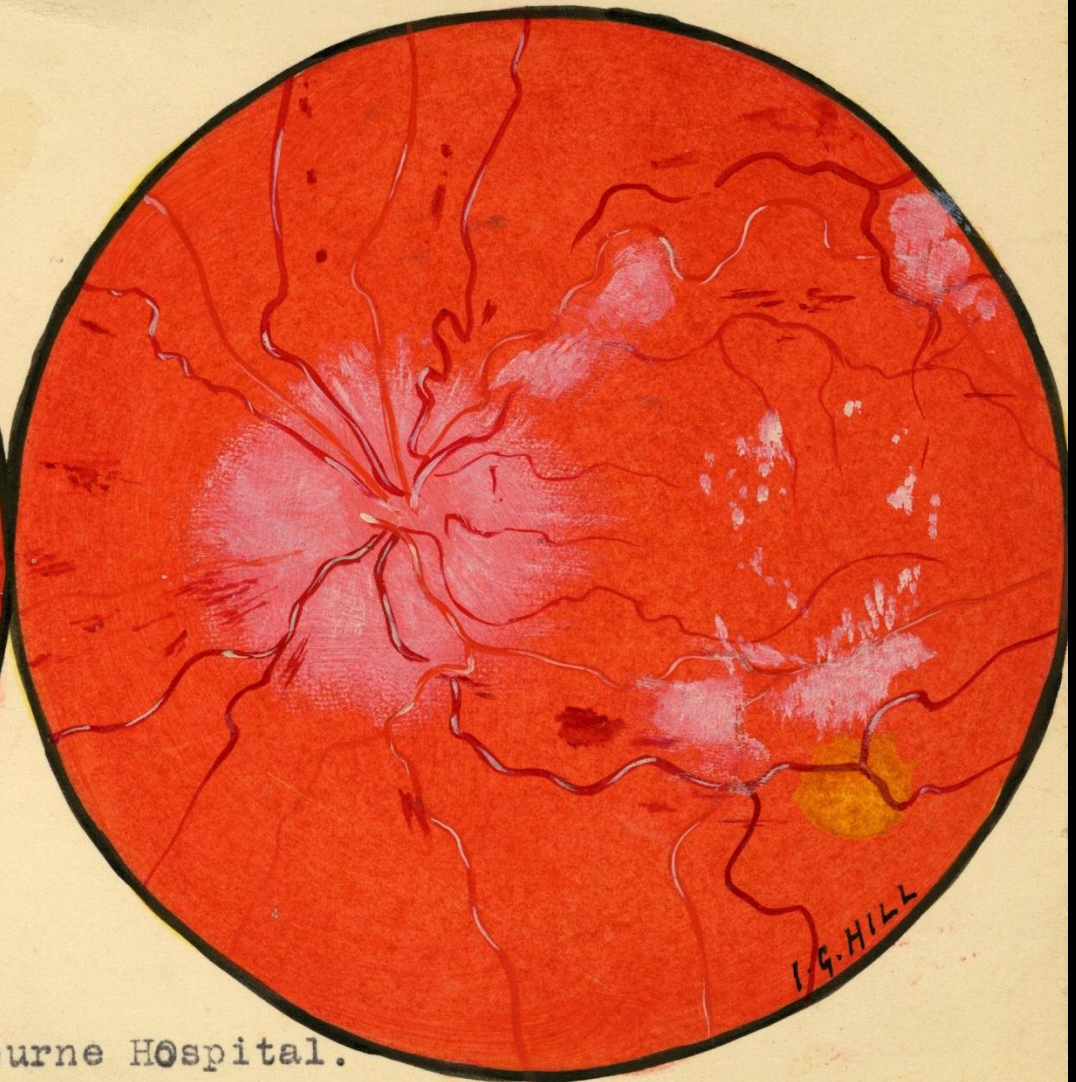Dr. R. F. Lowe.

49years

29/7/54



I.G. HILL



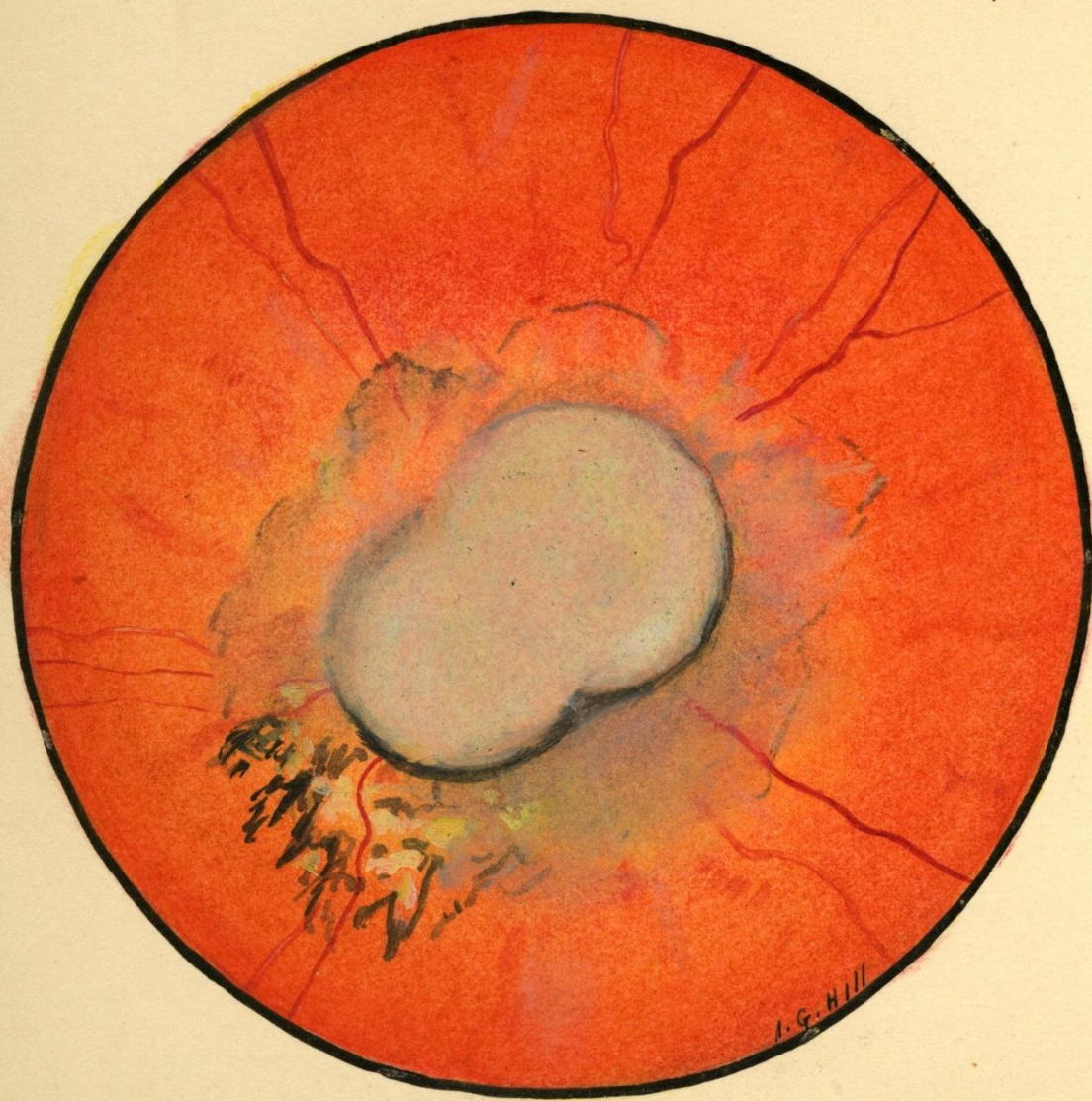
I.G. HILL

Royal Melbourne Hospital.

B. 1825.

6 yrs.

/50.



72 yrs. Eye & Ear Hospital. M2447. 26/6/50.

