


MONET AND HIS CATARACTS

- In 1912 Monet consulted several Parisian ophthalmologists who diagnosed nuclear sclerotic cataracts.
- Ophthalmologist Dr. Charles Coutela noted that Monet's right eye could only discern light perception and its direction, while his left eye's visual acuity was 1/10.
- Although cataract surgery was well established by this time, Monet was reluctant to proceed as fellow artists Honoré Daumier and Mary Cassatt had undergone cataract surgery with poor outcomes.



Dr. Charles Coutela,
Parisian Ophthalmologist 1934

MONET AND HIS CATARACTS

- Due to Monet's reluctance to proceed with surgery, Dr Coutela prescribed a mydriatic (eucatropine hydrochloride) for his left eye.
- Monet's letter to Dr Coutela:
"It is all simply marvelous. I have not seen so well for a long time, so much so that I regret not having seen you sooner. The drops have permitted me to paint good things rather than the bad paintings which I had persisted in making when seeing nothing but fog."
- However, despite the eye drops Monet's vision continued to deteriorate.


MONET AND HIS CATARACTS

- In October 1922 Monet contacted Dr. Coutela to make plans for cataract surgery for his right eye in January 1923.

Dr. Coutela:

“I proceeded directly to extract the cataract, extracapsularly, washing out as much of the lens as was possible. That evening the anterior chamber was reformed, which was a great encouragement for me.”

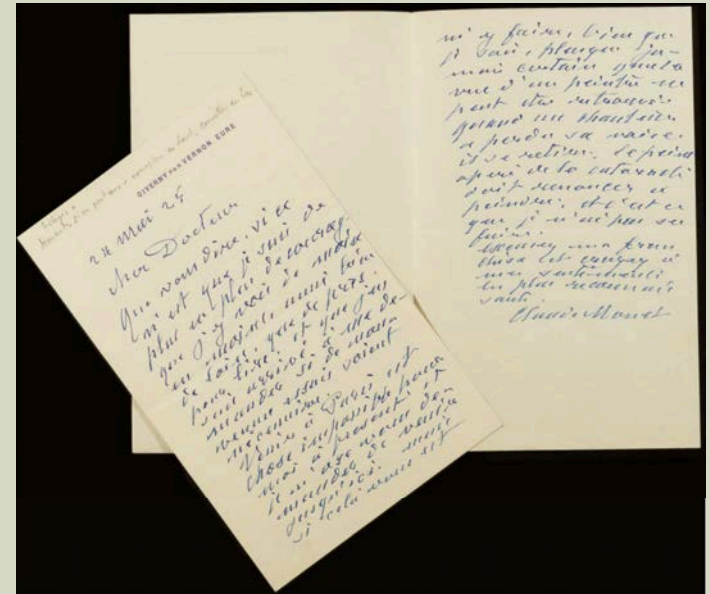
- Monet was left aphakic and immobilised for 10 days postoperatively lying flat, with his head held in position with sandbags.
- Three weeks after his surgery, Monet was given a pair of aphakic glasses.



Monet recovering from cataract surgery 1923.

MONET AND HIS CATARACTS

- Monet soon became disgruntled as his vision soon deteriorated again due to the development of posterior capsular opacities.
- Monet's letter to Dr. Coutela:
"It is to my great chagrin that I regret having had this fatal operation. Pardon me for speaking so frankly and let me tell you that it is criminal to have put me in this situation."
- Dr. Coutela convinced Monet to undergo a second operation, a posterior capsulotomy, which was successfully performed in Monet's home in June 1923.



Monet's letter to Dr Coutela 25th May 1923

MONET AND HIS CATARACTS

- Postoperatively, Monet's visual acuity in his right eye was 20/30 with a correction of +10.0/+4.0 X 90°. Despite this Monet complained of distorted vision and excessive blue.

"It's filthy, it's disgusting, I see nothing but blue. I no longer see red or yellow. This annoys me terribly because I know these colours exist. I am terribly sad and discouraged. Life is a torture for me."




Monet's house from the rose garden: left 1922, right 1924. Note the predominance of blues post cataract surgery.

MONET AND HIS CATARACTS

- During this time, Monet unhappy with his vision and paintings destroyed much of his artwork.
- In 1924 Monet consulted with Dr. Jaques Mawas, another Parisian ophthalmologist who worked for Zeiss Optical. He prescribed Monet a new set of lenses with an added yellow-green tint. These were +14.0/+7.0 X 90° for the right eye, and plano for the left eye.

“I can see green again, red, and at last, an attenuated blue.”

“I have recovered my true vision. I am happily seeing everything again and I am working with ardor.”



Top: Monet's aphakic glasses with a yellow-green tint. Note the curvature of the right lens, and the flat darker left lens.

Bottom: Monet wearing his glasses, 1926.

MONET'S FINAL YEARS

- Now pleased with his vision, Monet continued to paint almost to the time of his death.
- At the age of 86 Monet passed away on the 5th of December 1926 from lung cancer caused by his smoking.
- Cataracts played a critical role in Monet's later work. Many considered his work during this time to be inferior to his earlier work, while others consider it to be an important step towards the abstract art of the 20th century.